



Dermatopatias da ponte e espelho nasal: abordagem clínico-diagnóstica

Prof. Dr. Rafael Rodrigues Ferreira



DERMATOVET
CURSOS

CN8202

DOENÇAS AUTO- IMUNES

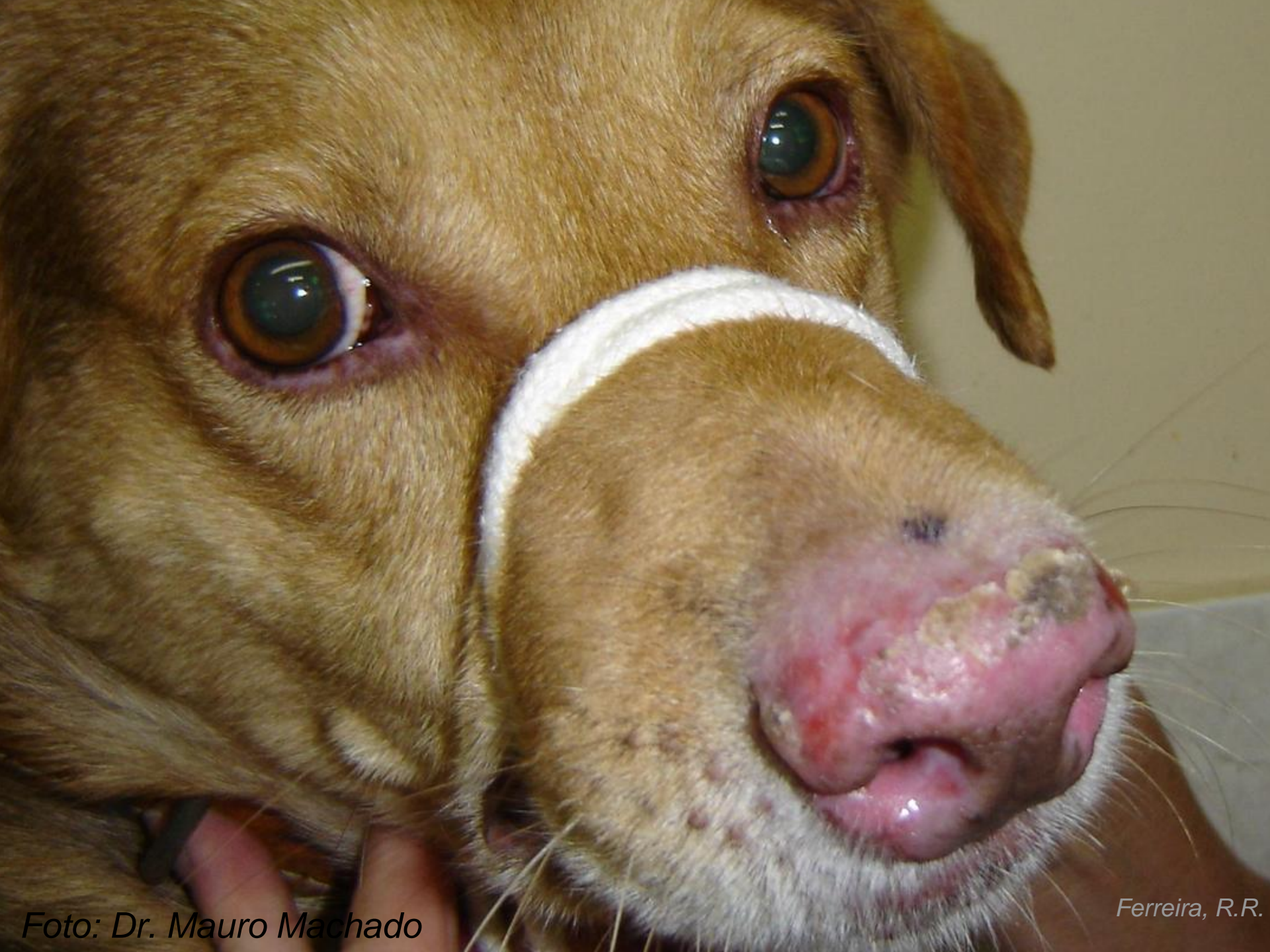

Foto: Dr. Mauro Machado

Ferreira, R.R.

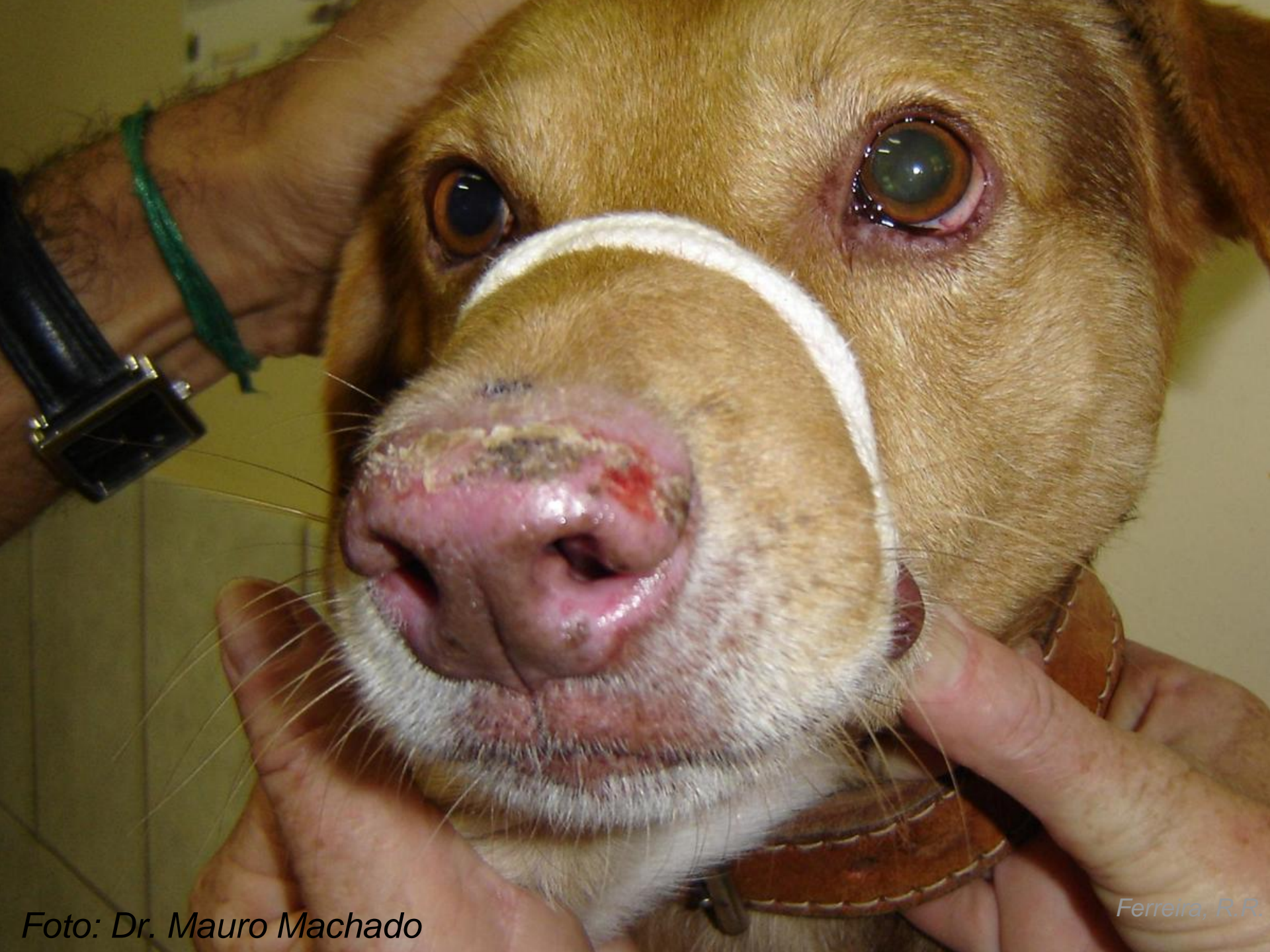
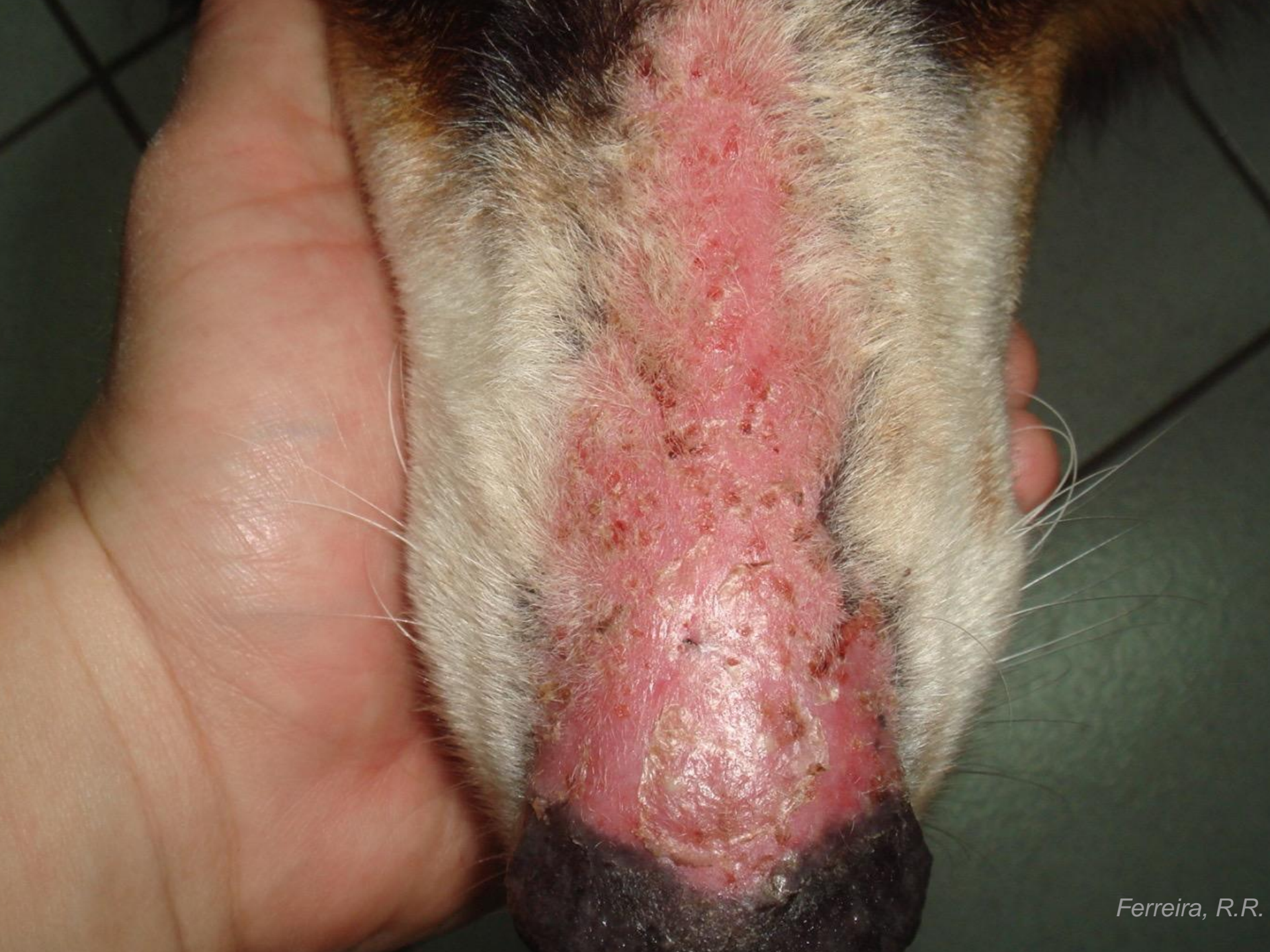
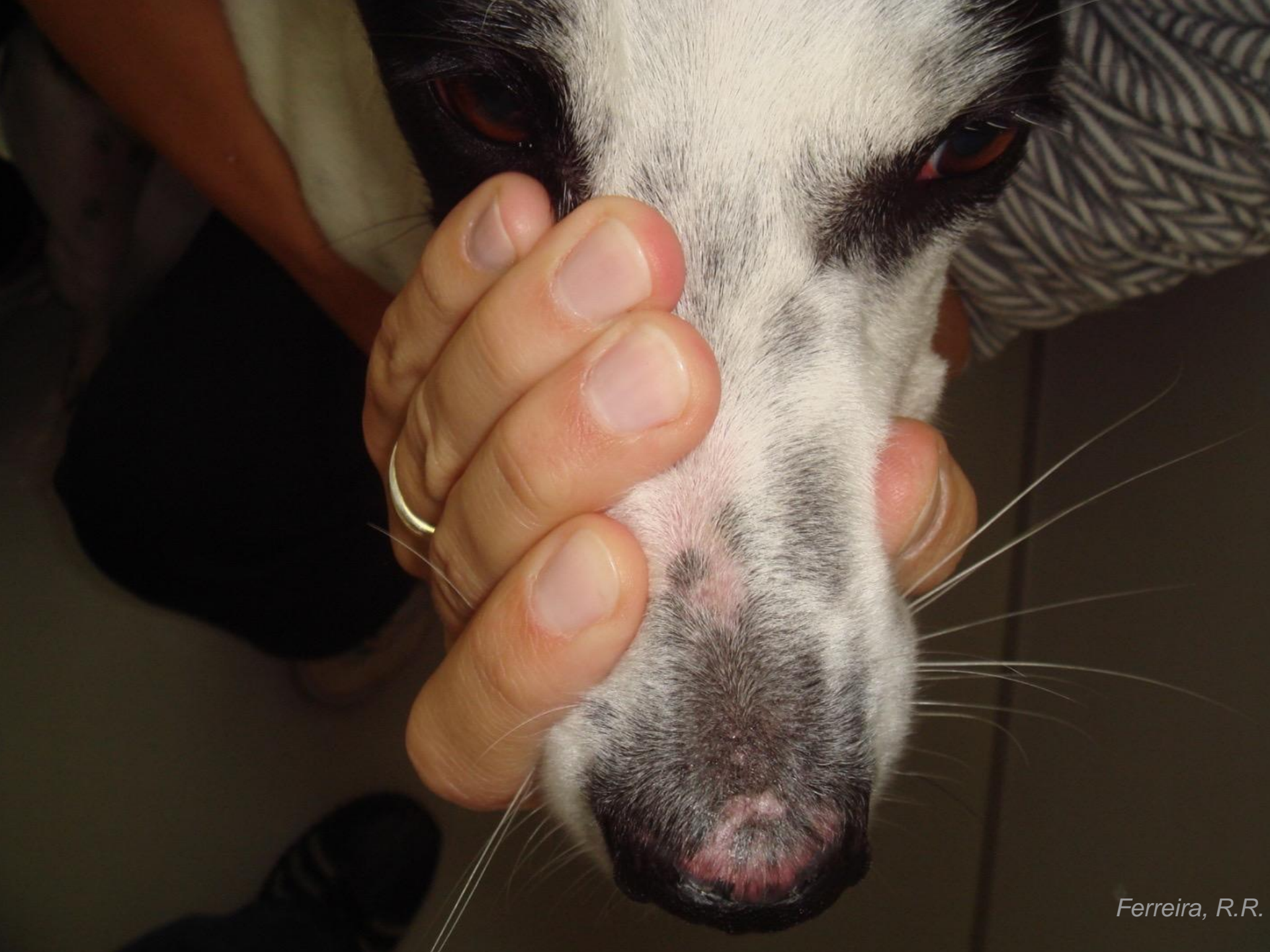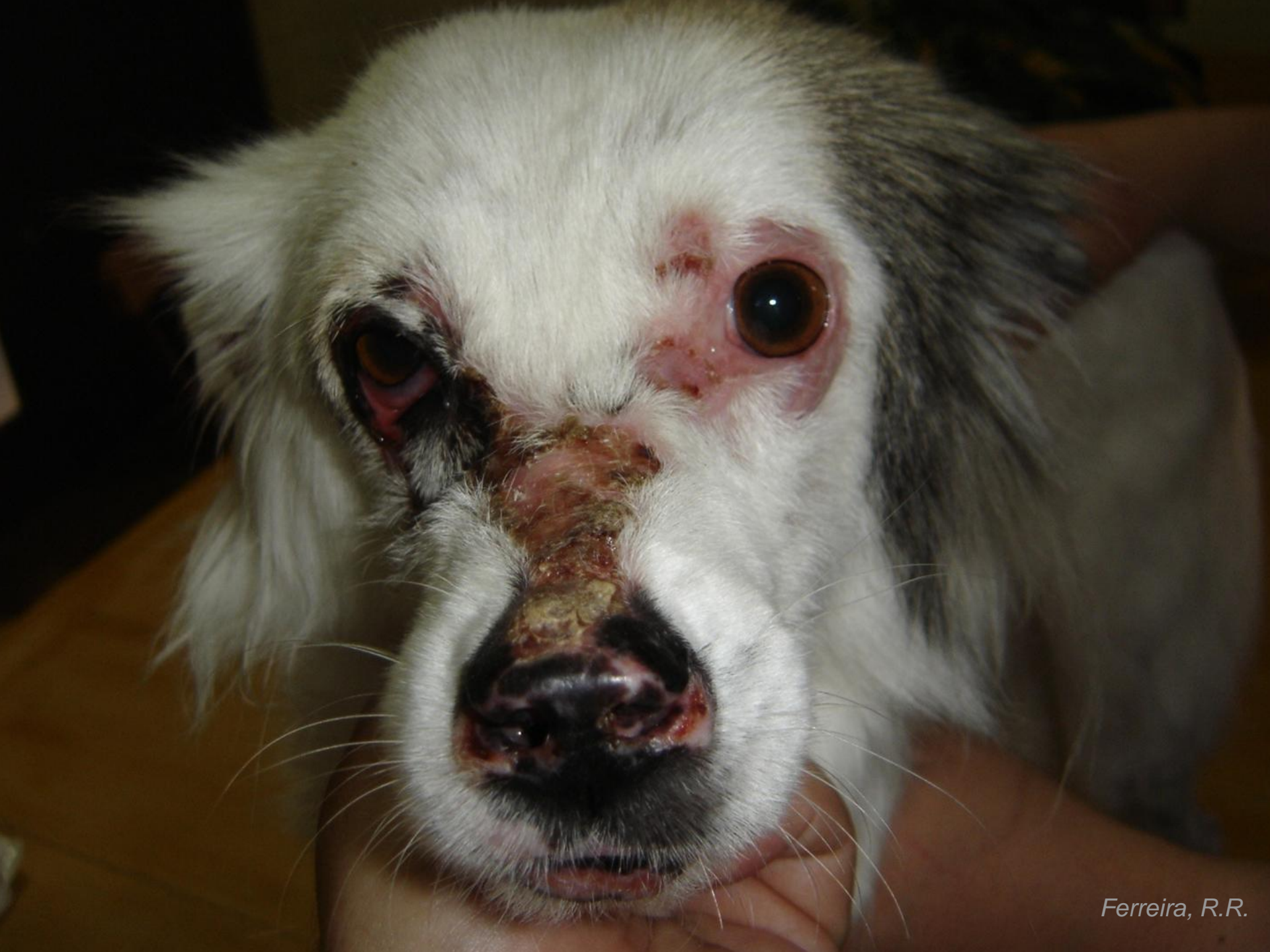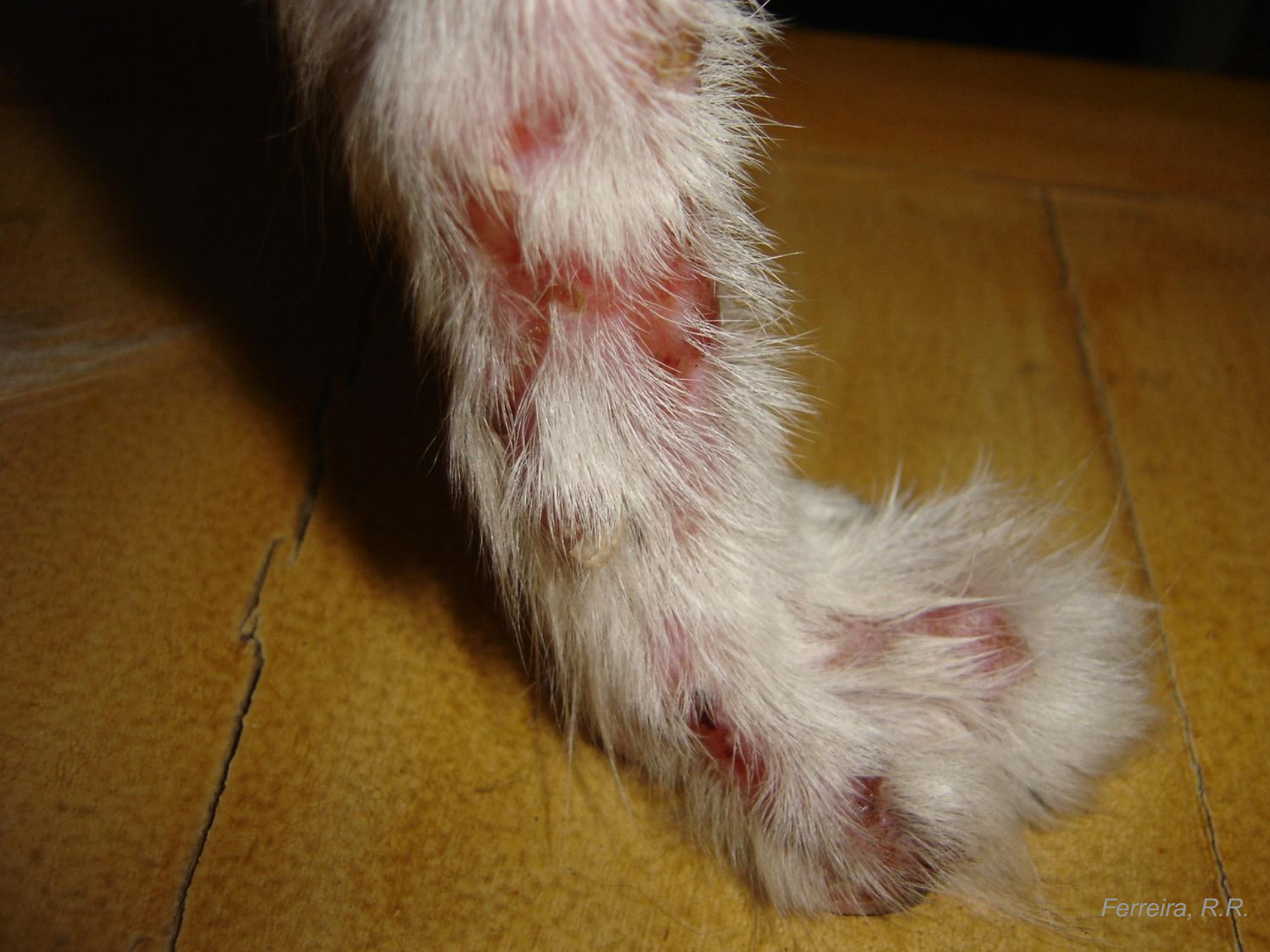Foto: Dr. Mauro Machado

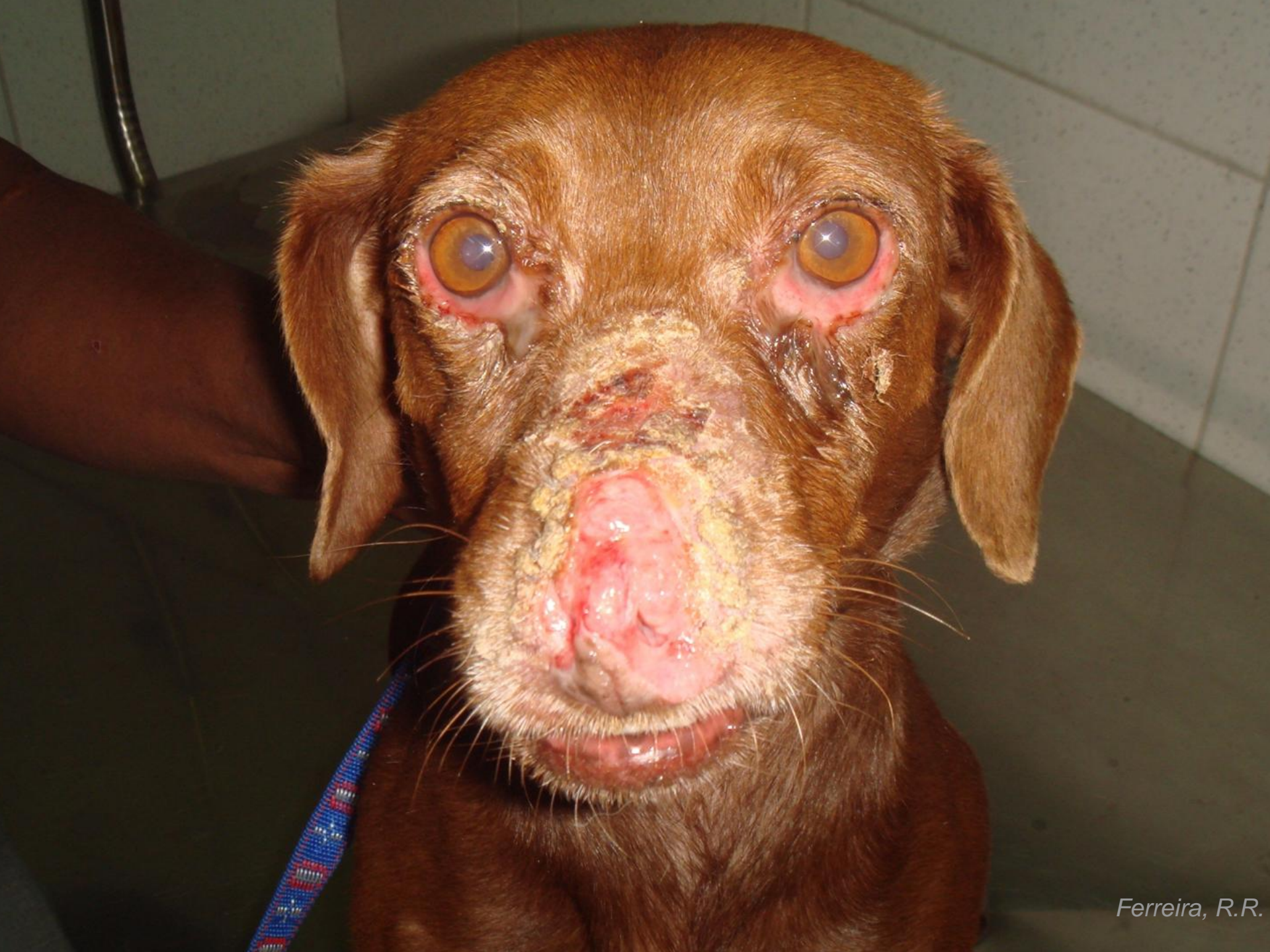Ferreira, R.R.

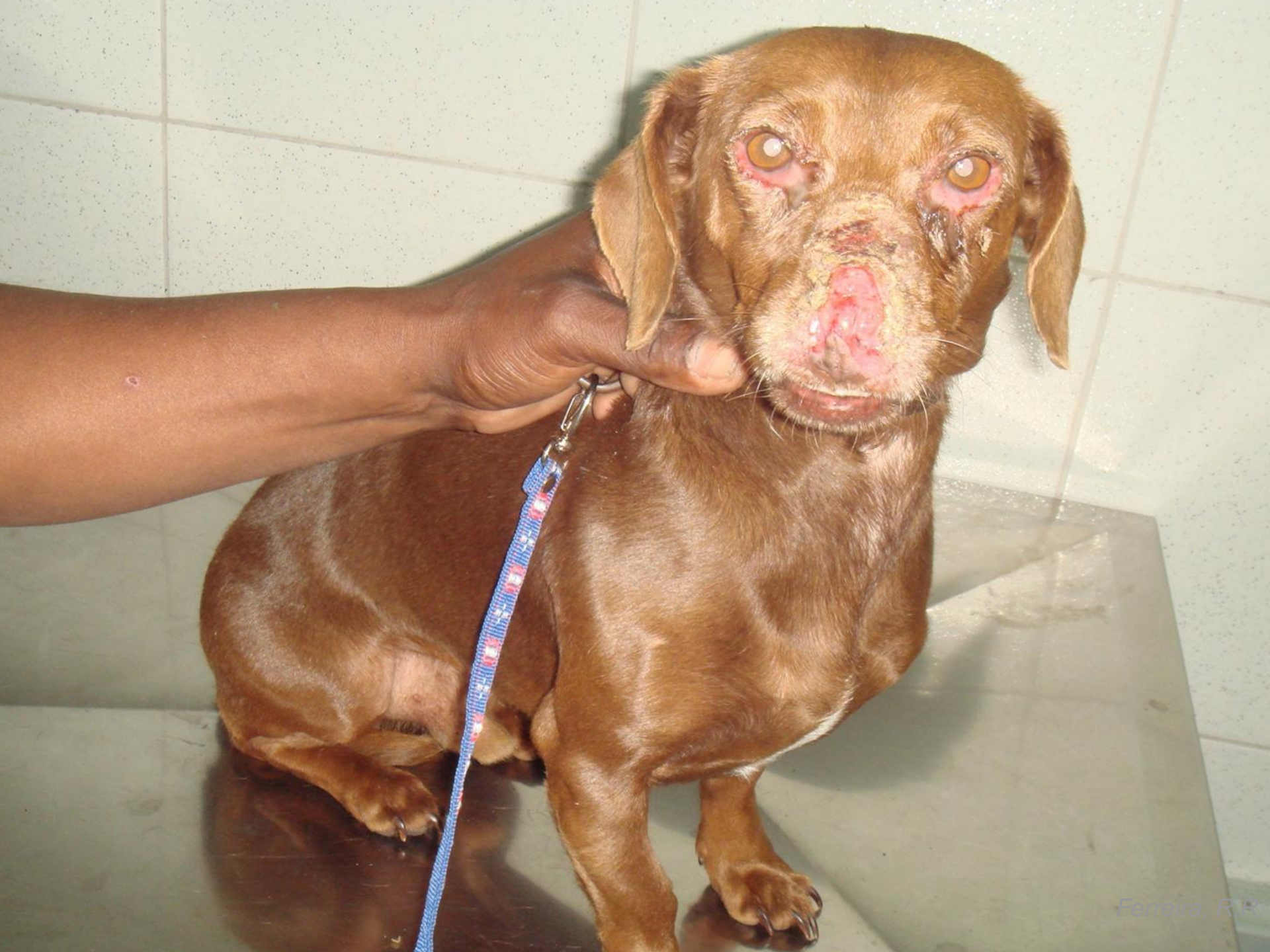


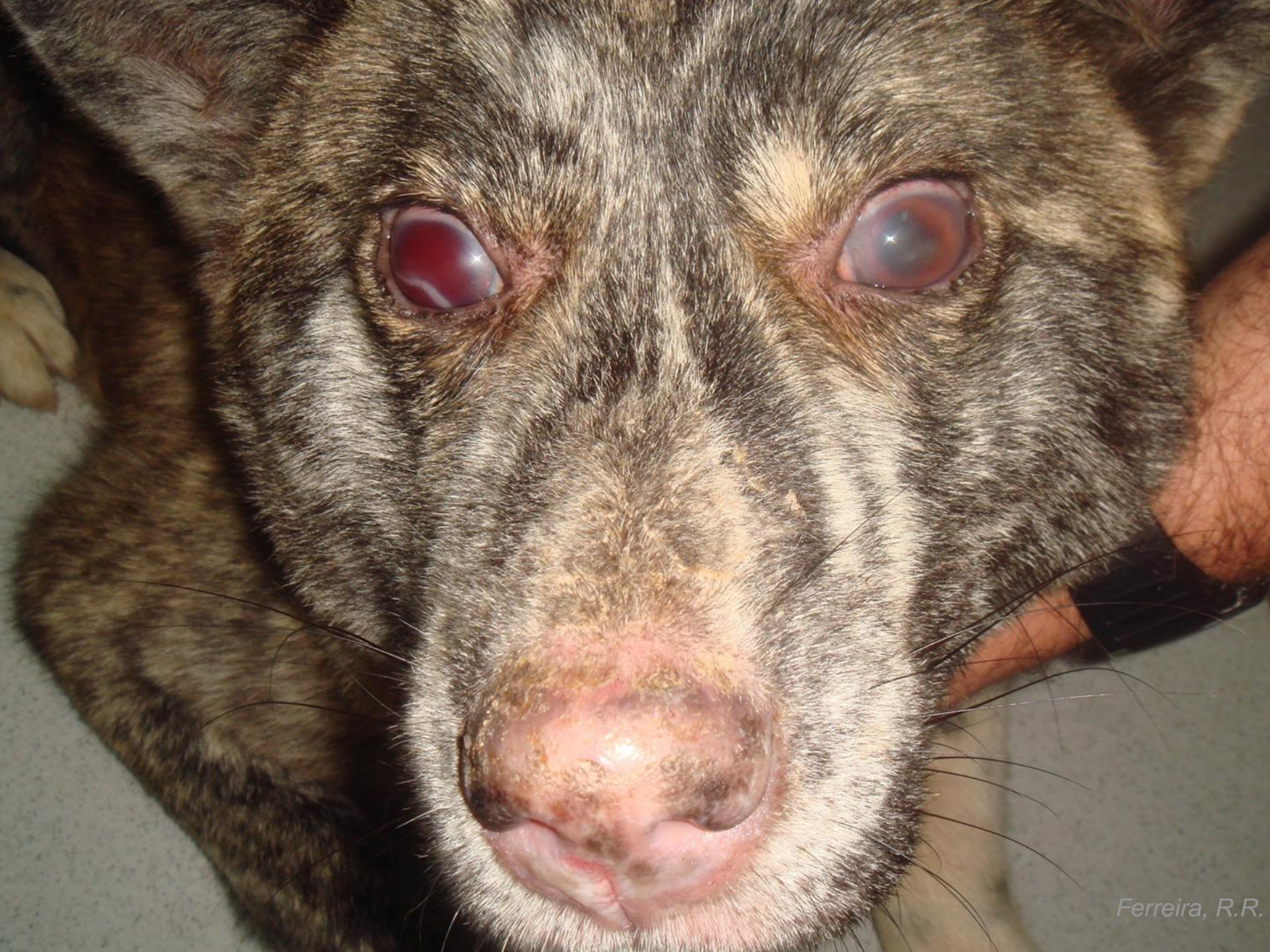








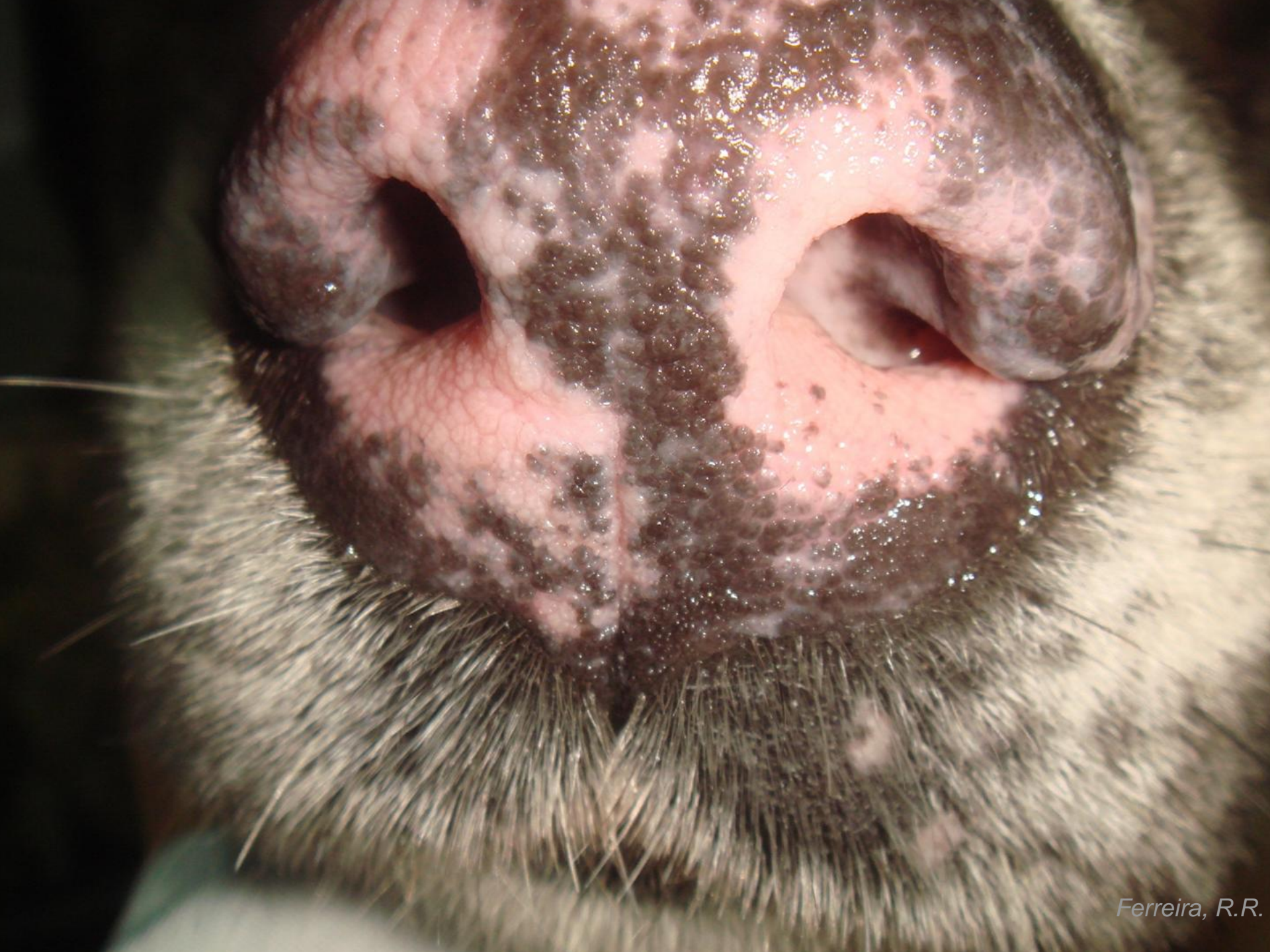


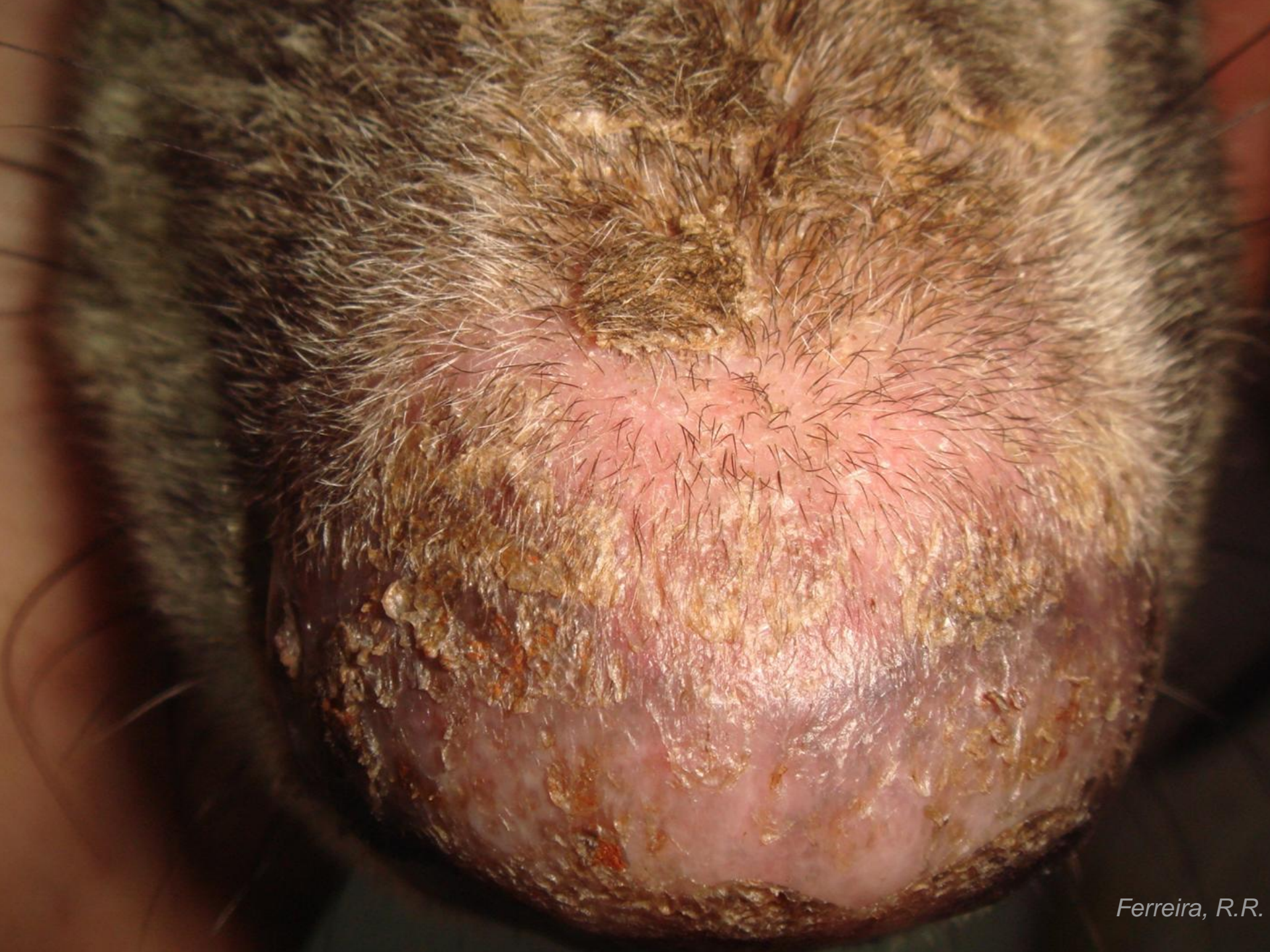
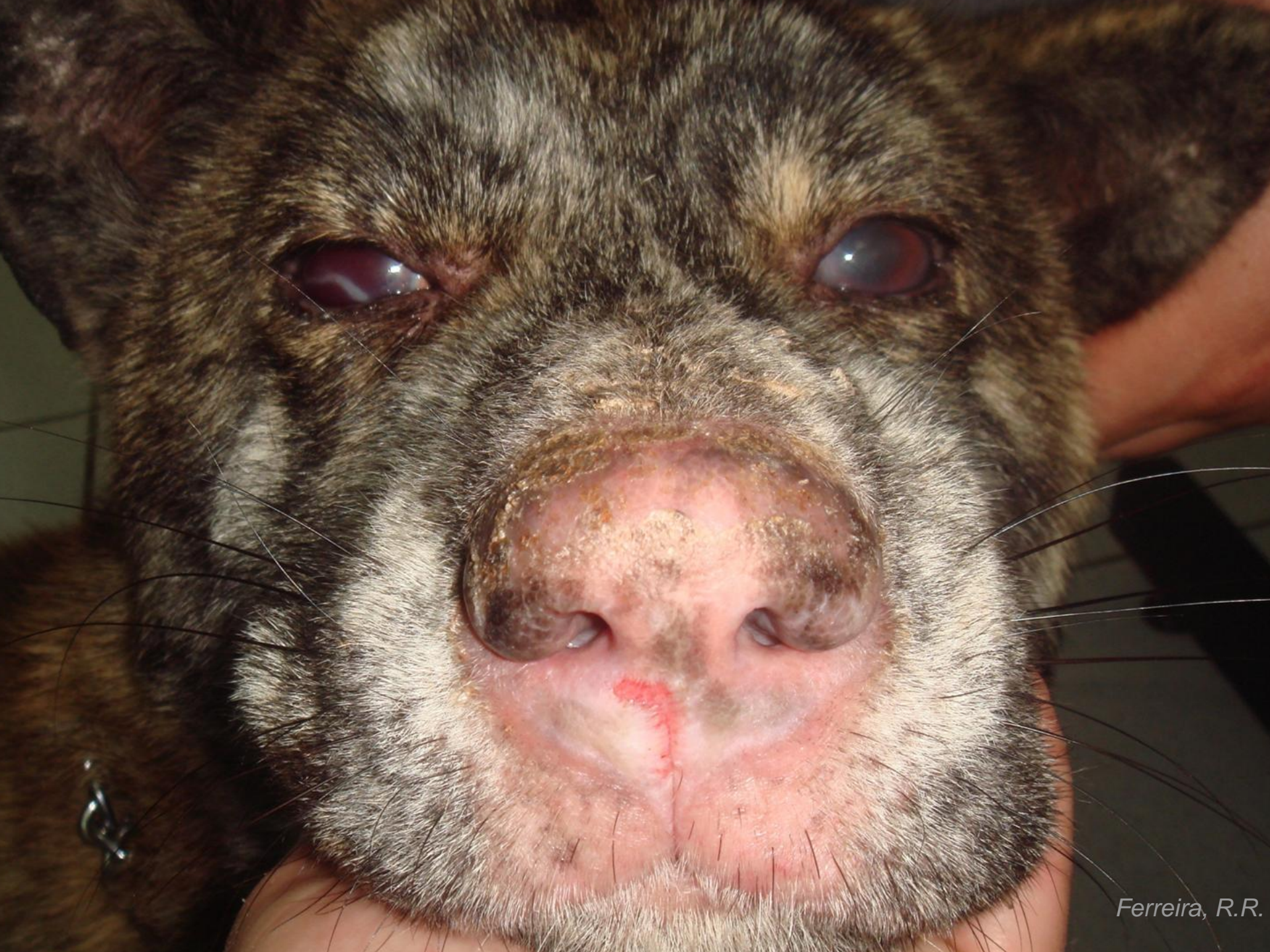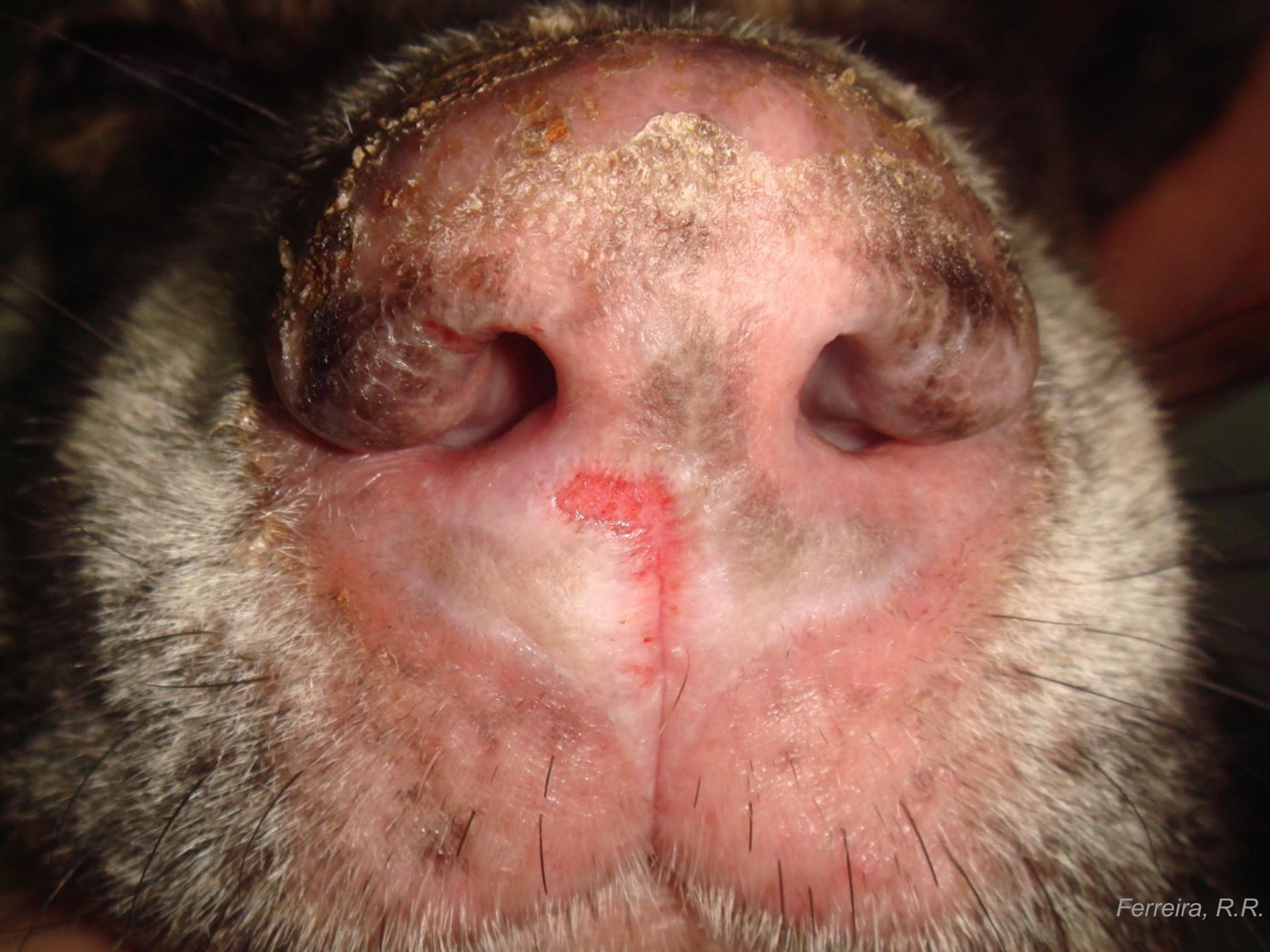Fotos: M.V. Simone Rocha

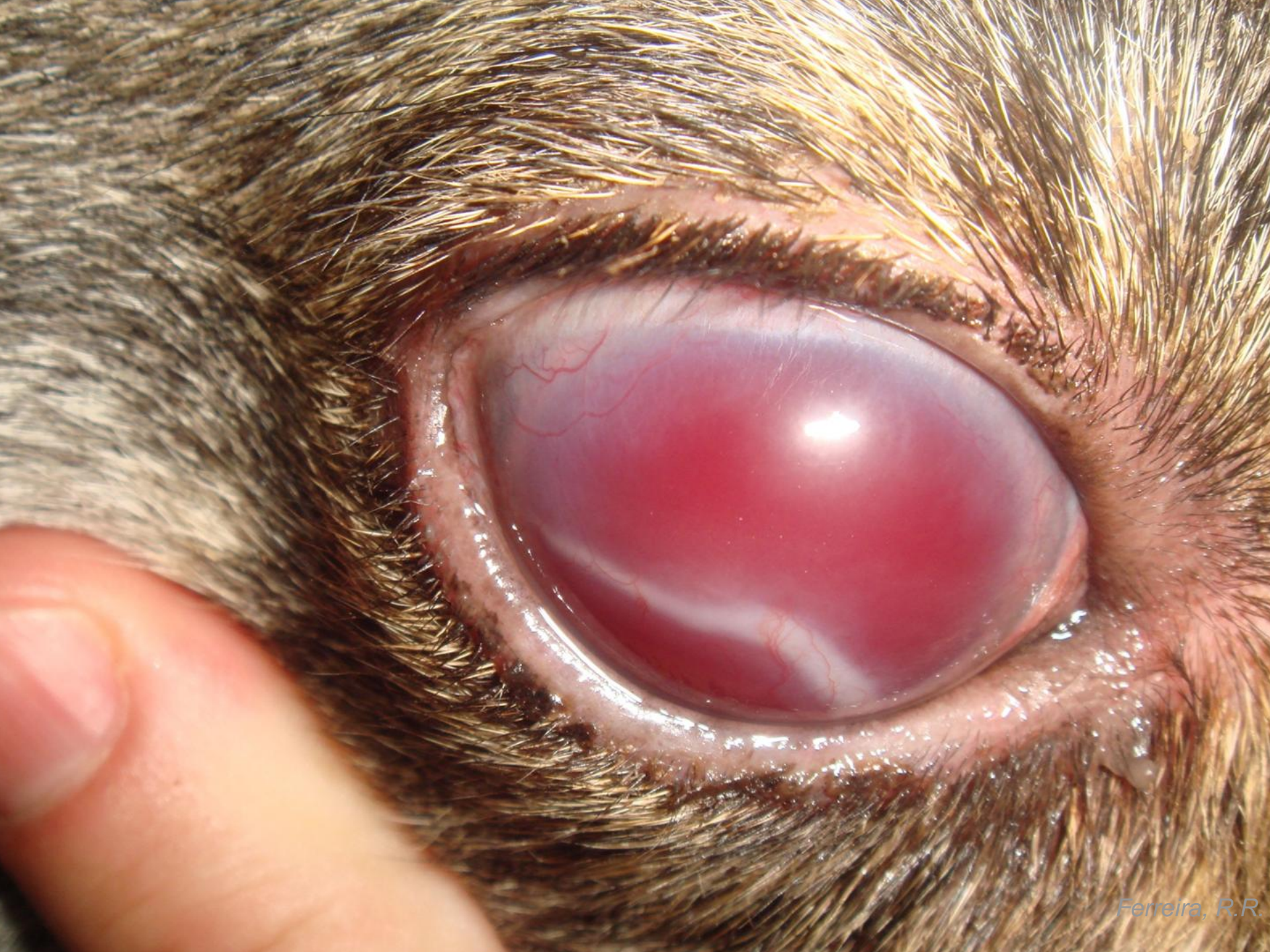Ferreira, R.R.

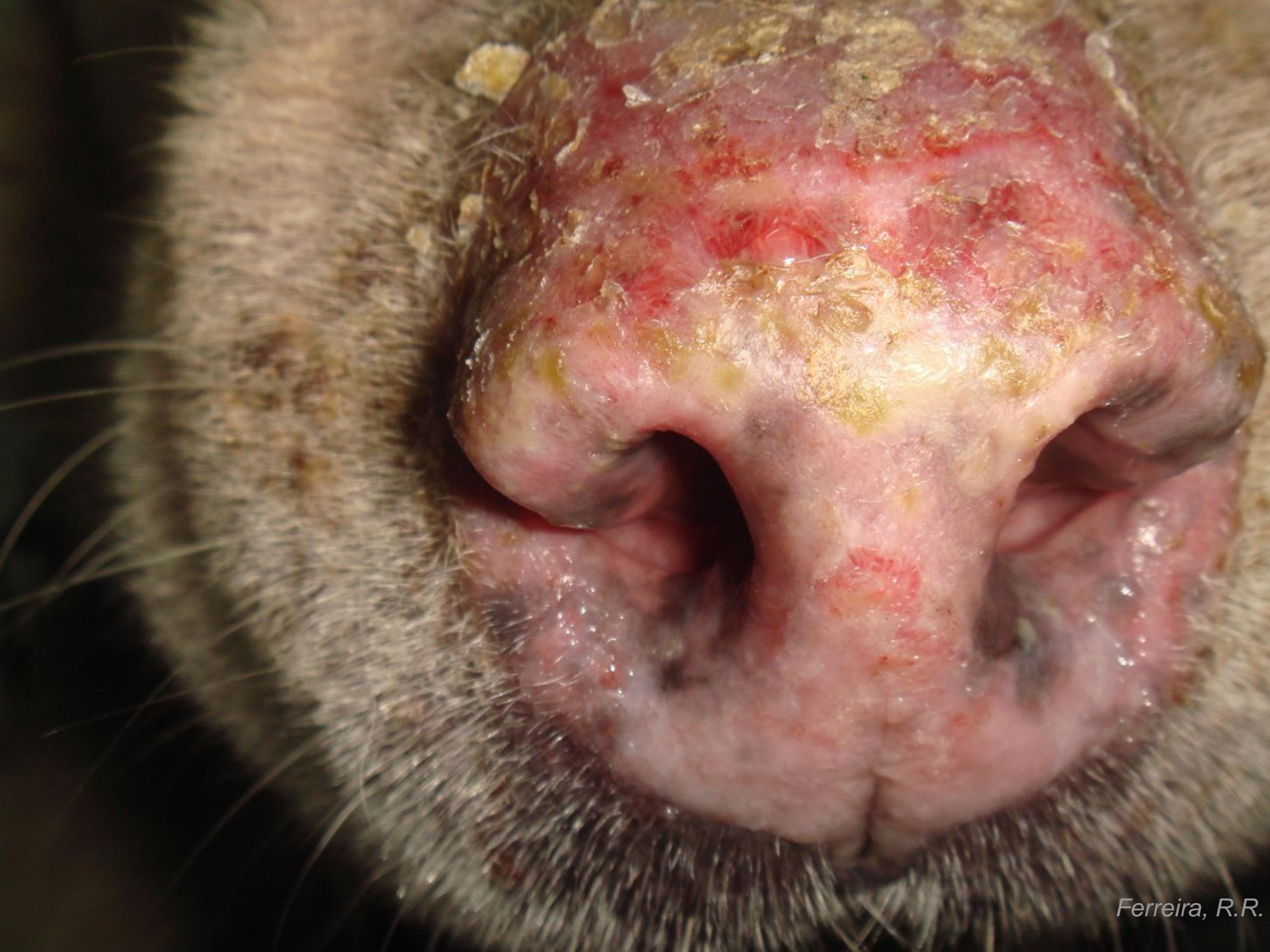


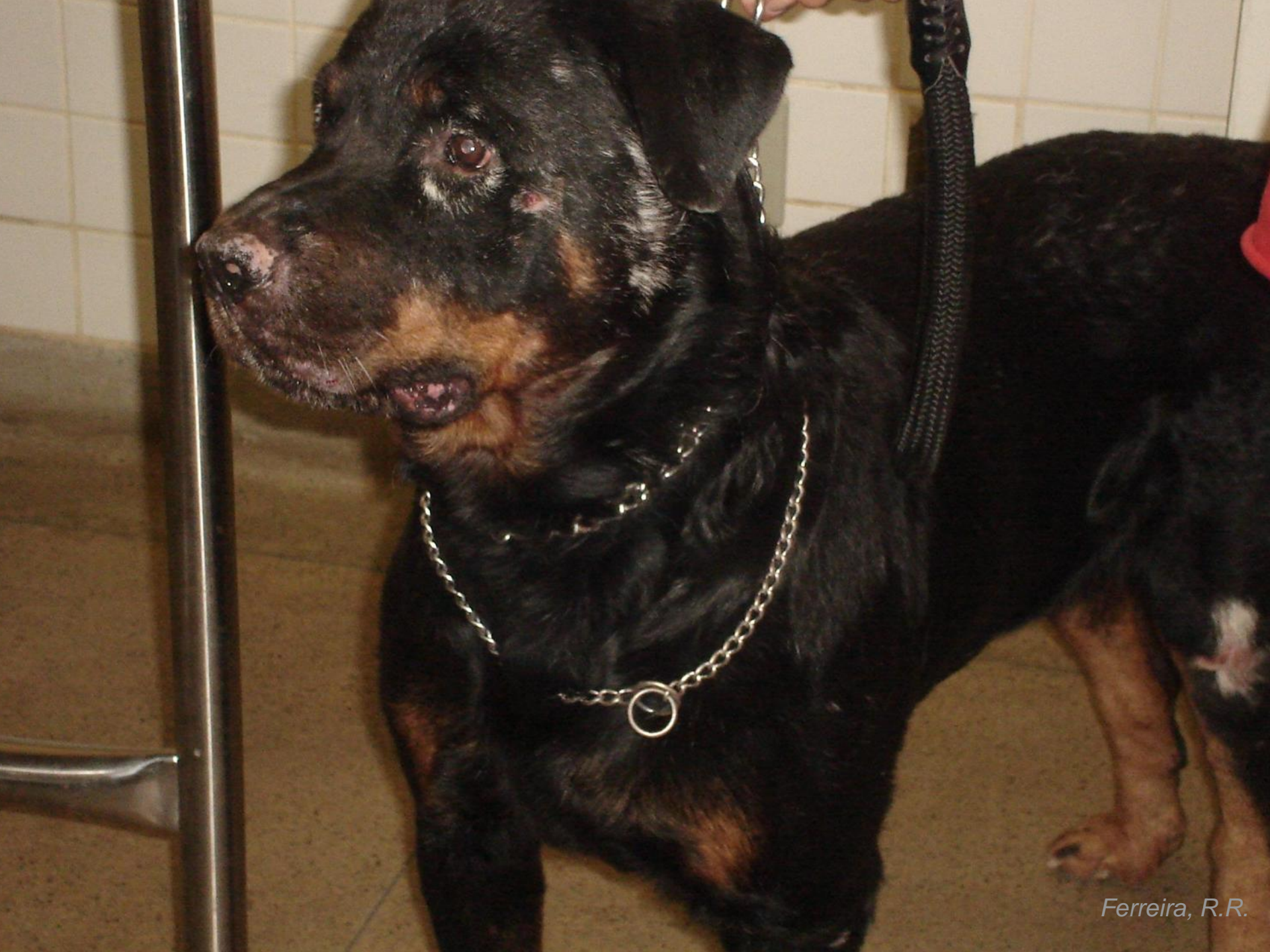










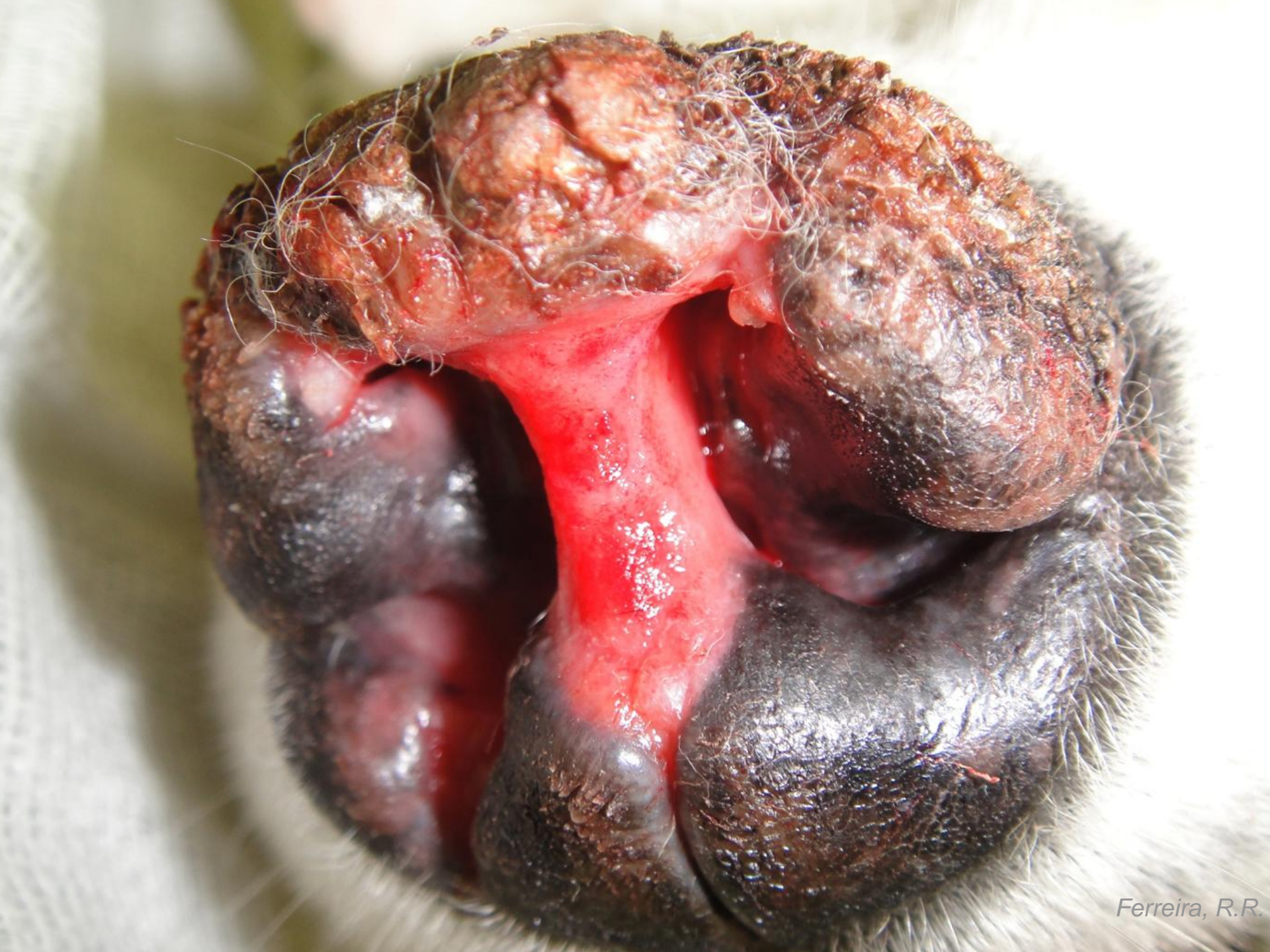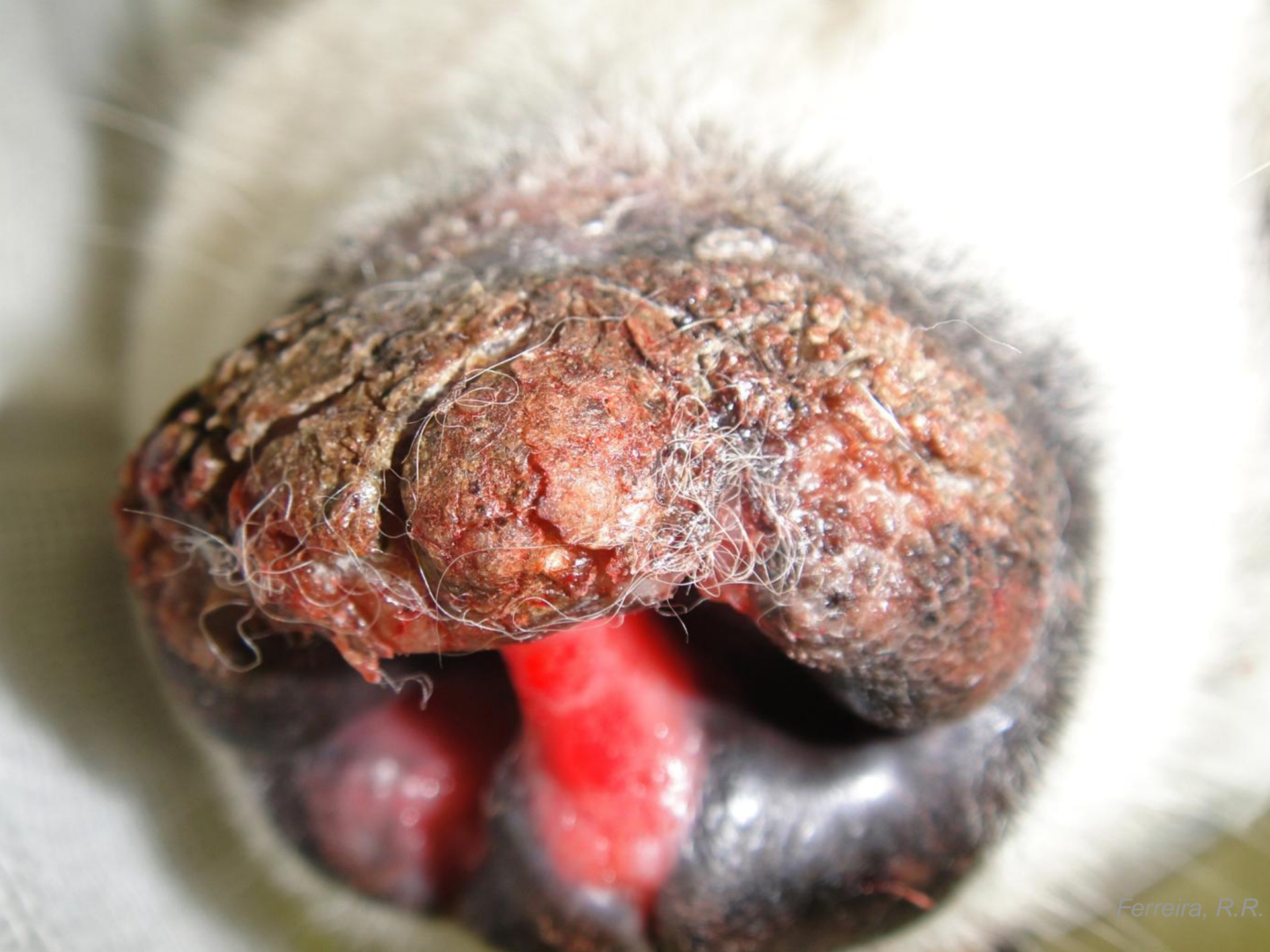Ferreira, R.R.

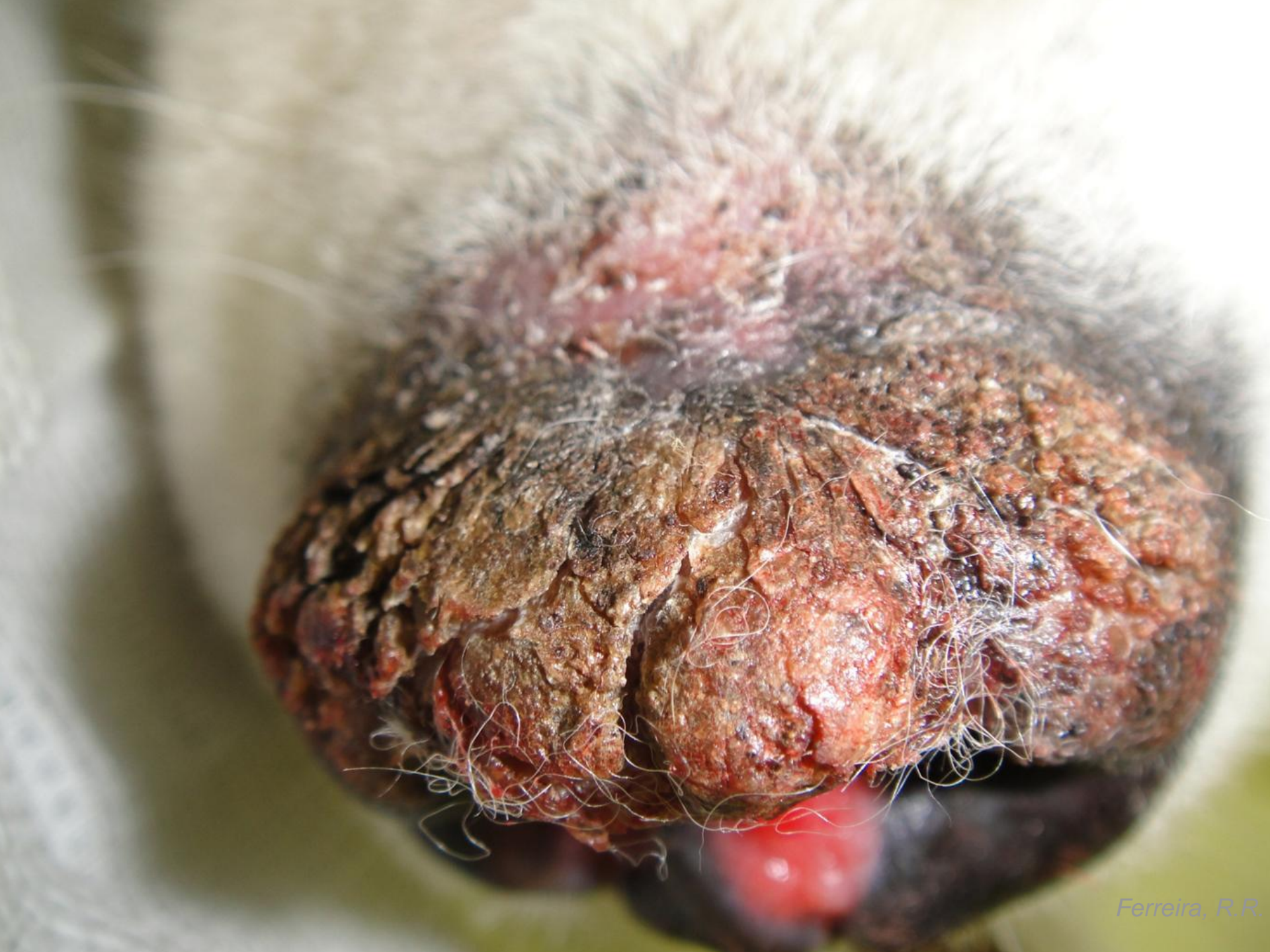

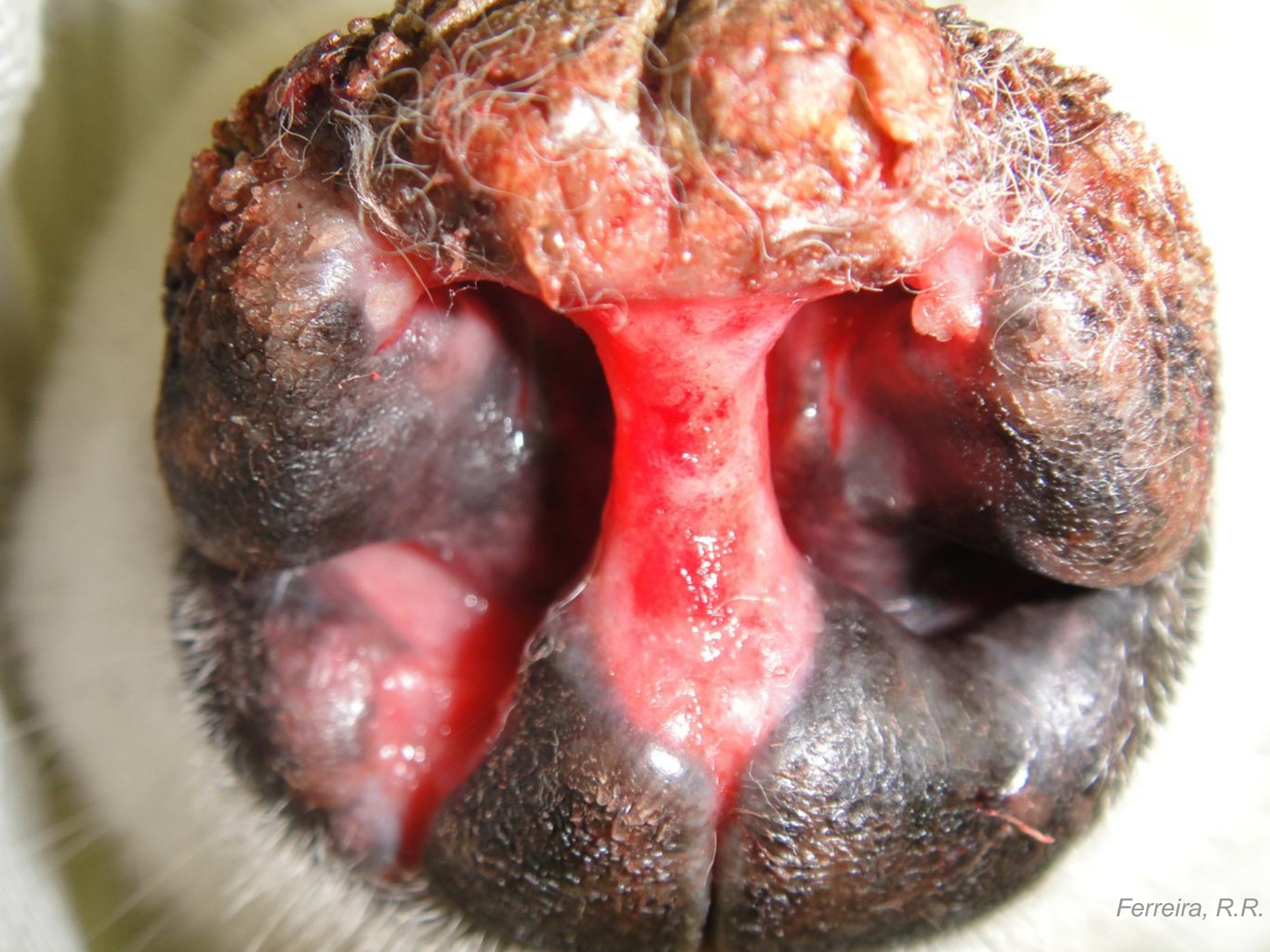Fotos: M.V. Simone Rocha

Ferreira, R.R.









CASE REPORT

Dermal arteritis of the nasal philtrum: surgery as an alternative to long-term medical therapy in two dogs

Journal of Small Animal Practice (2009)

50, 99–103

DOI: 10.1111/j.1748-5827.2008.00691.x

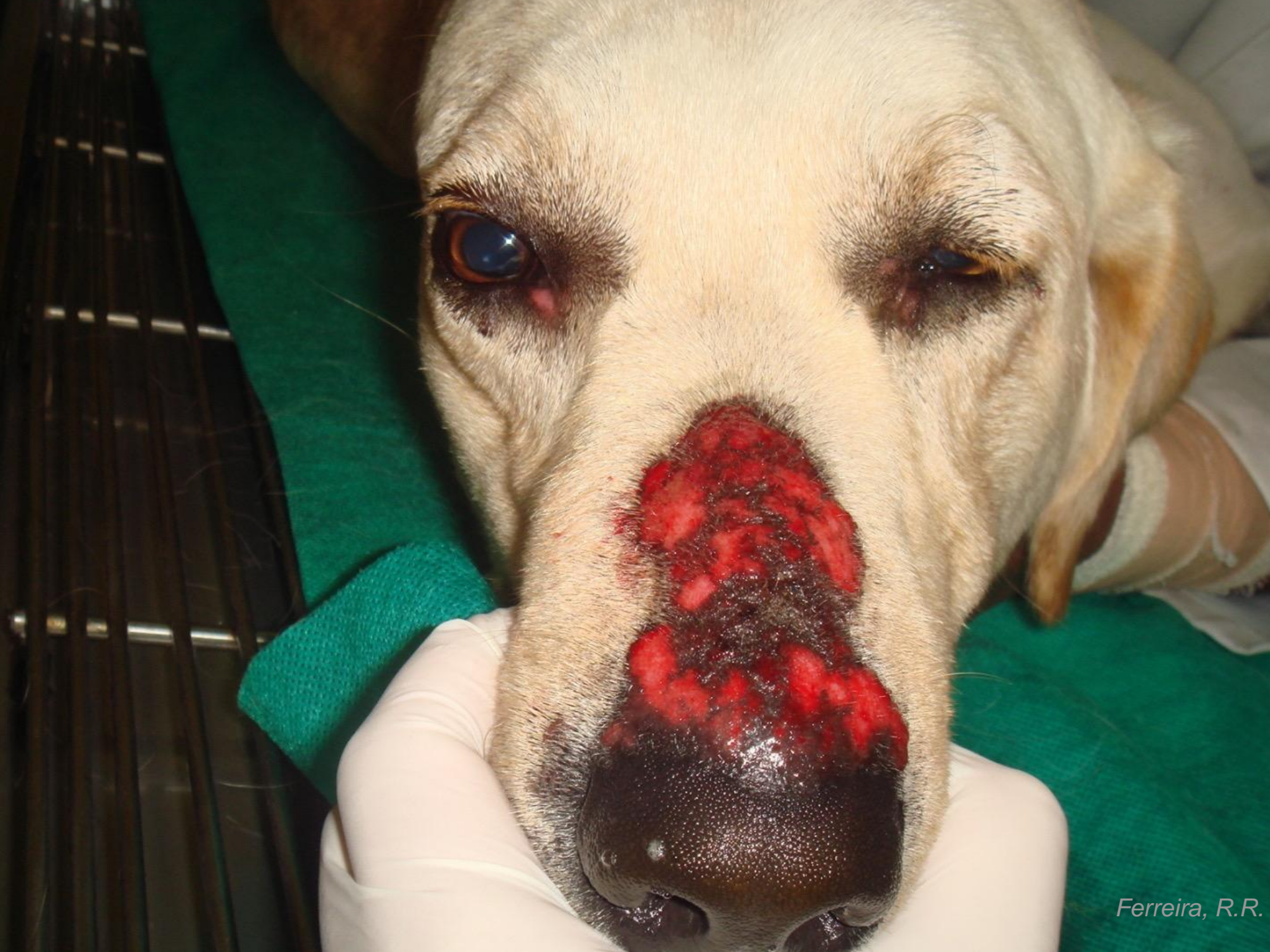TORRES, S. M. F., O'BRIEN T. O. & SCOTT D. W. (2002)
Dermal arteritis of the nasal philtrum in a Giant Schnauzer and three Saint Bernard dogs. *Veterinary Dermatology* **13**, 275-281

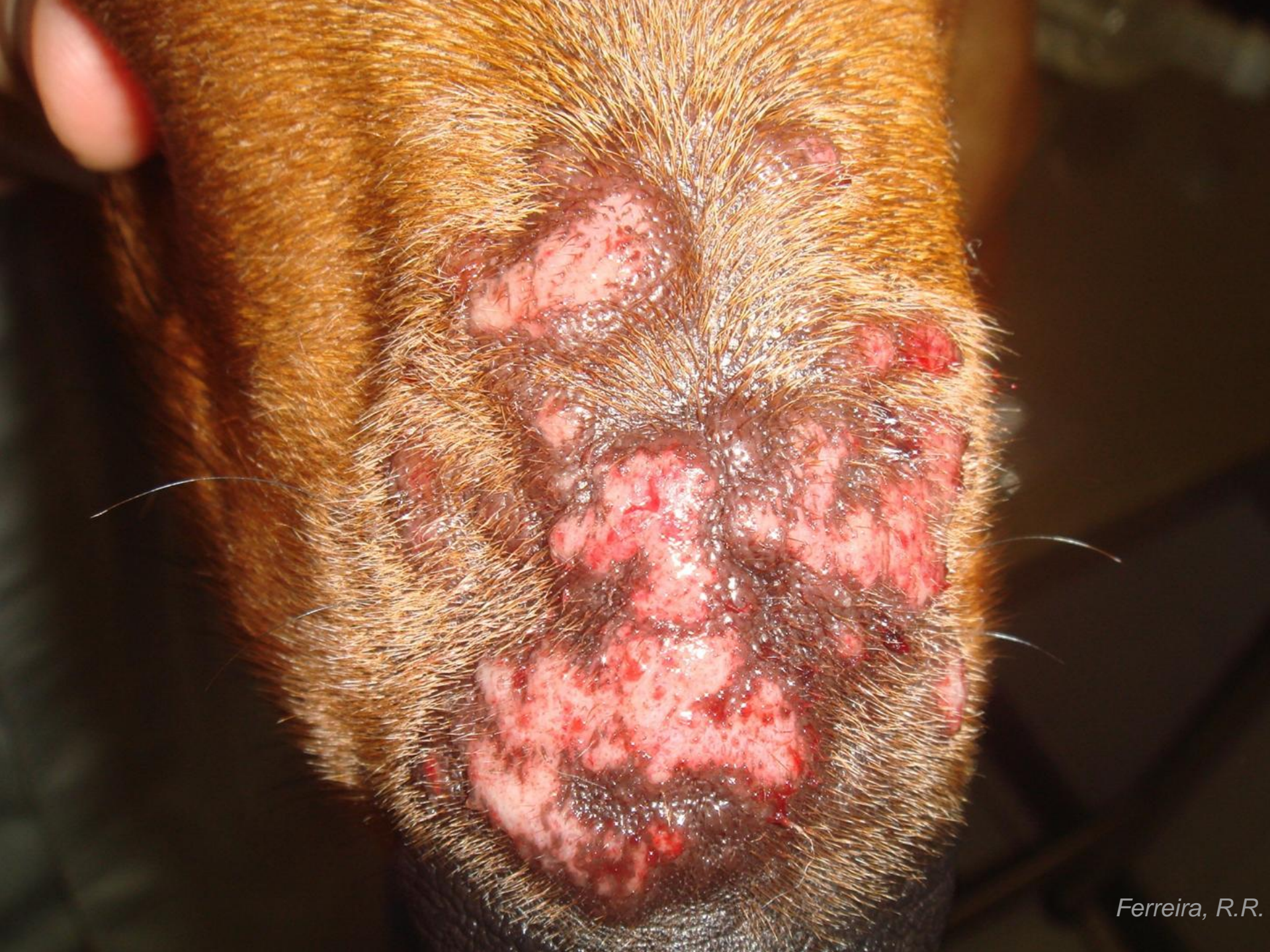

DERMATOVET
CURSOS

CRK202

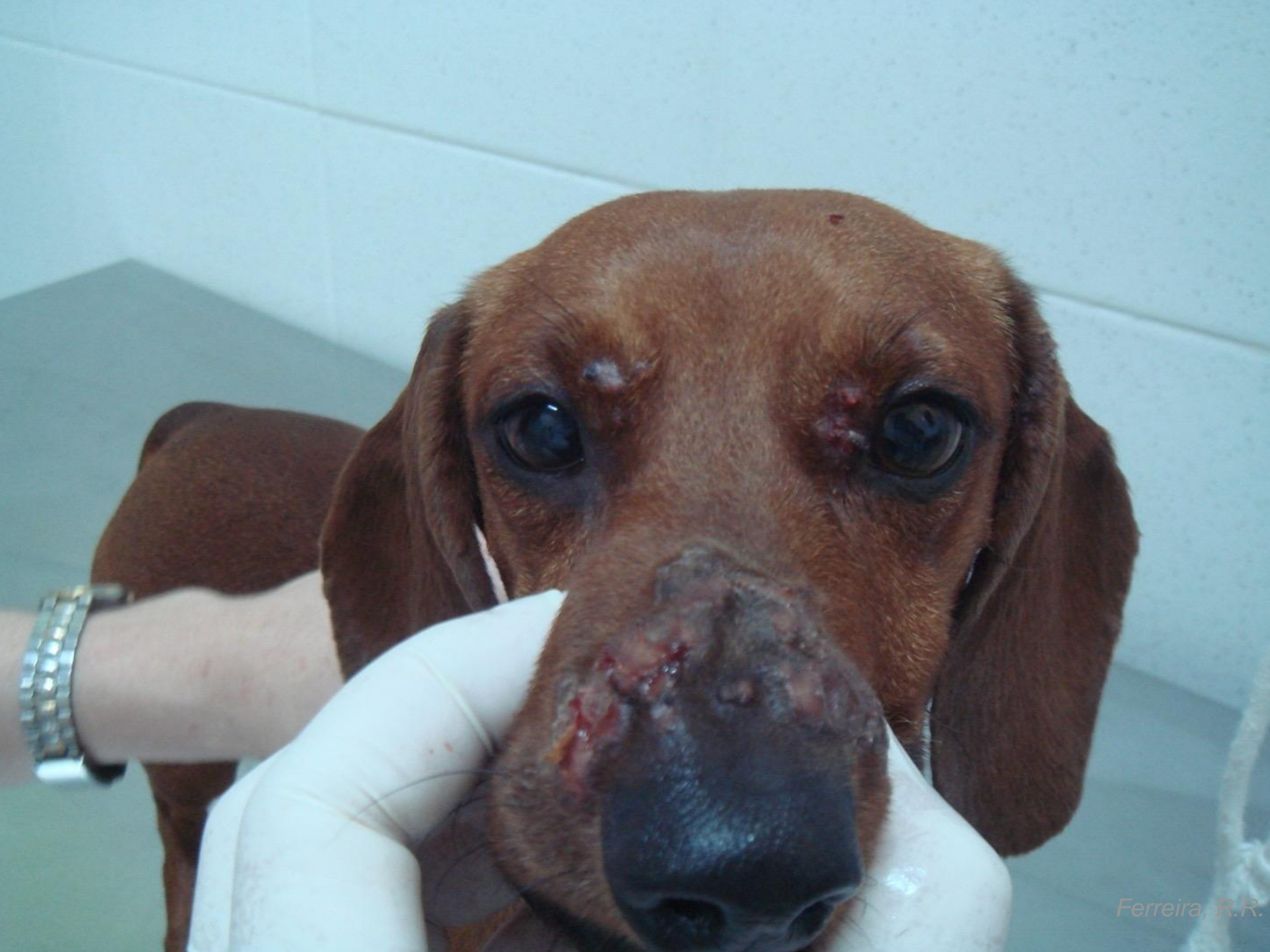DOENÇAS INFLAMATÓRIAS

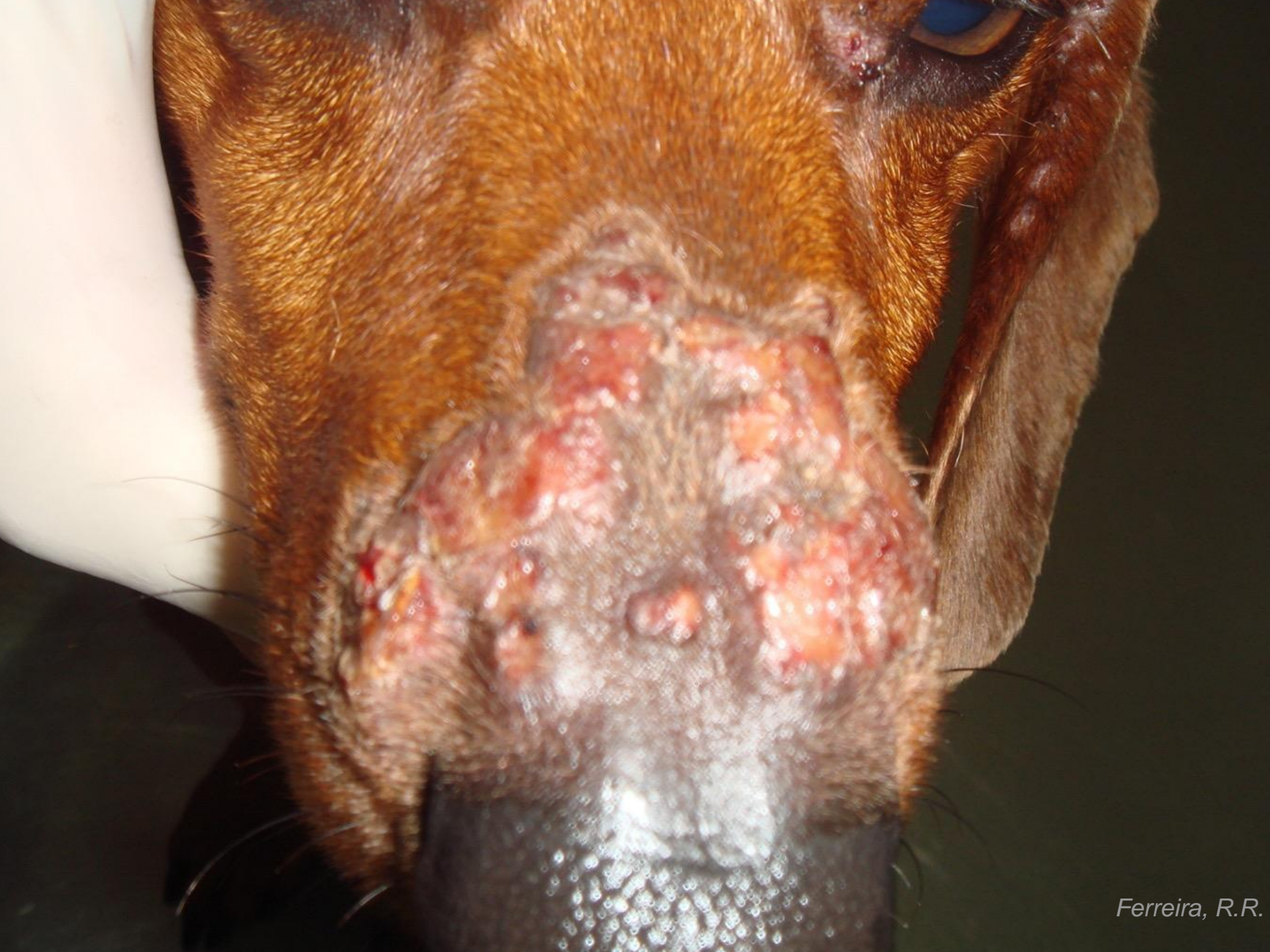


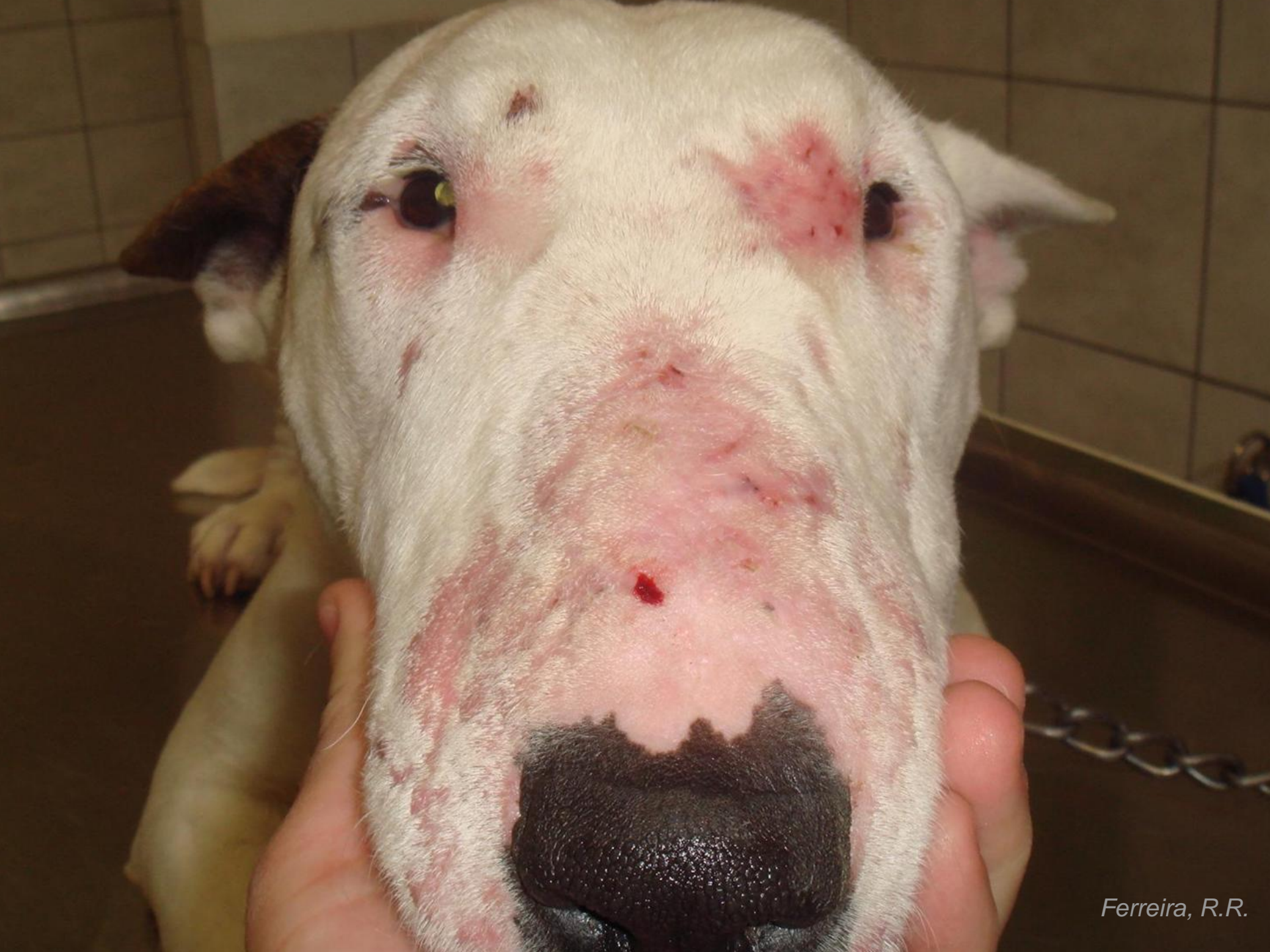


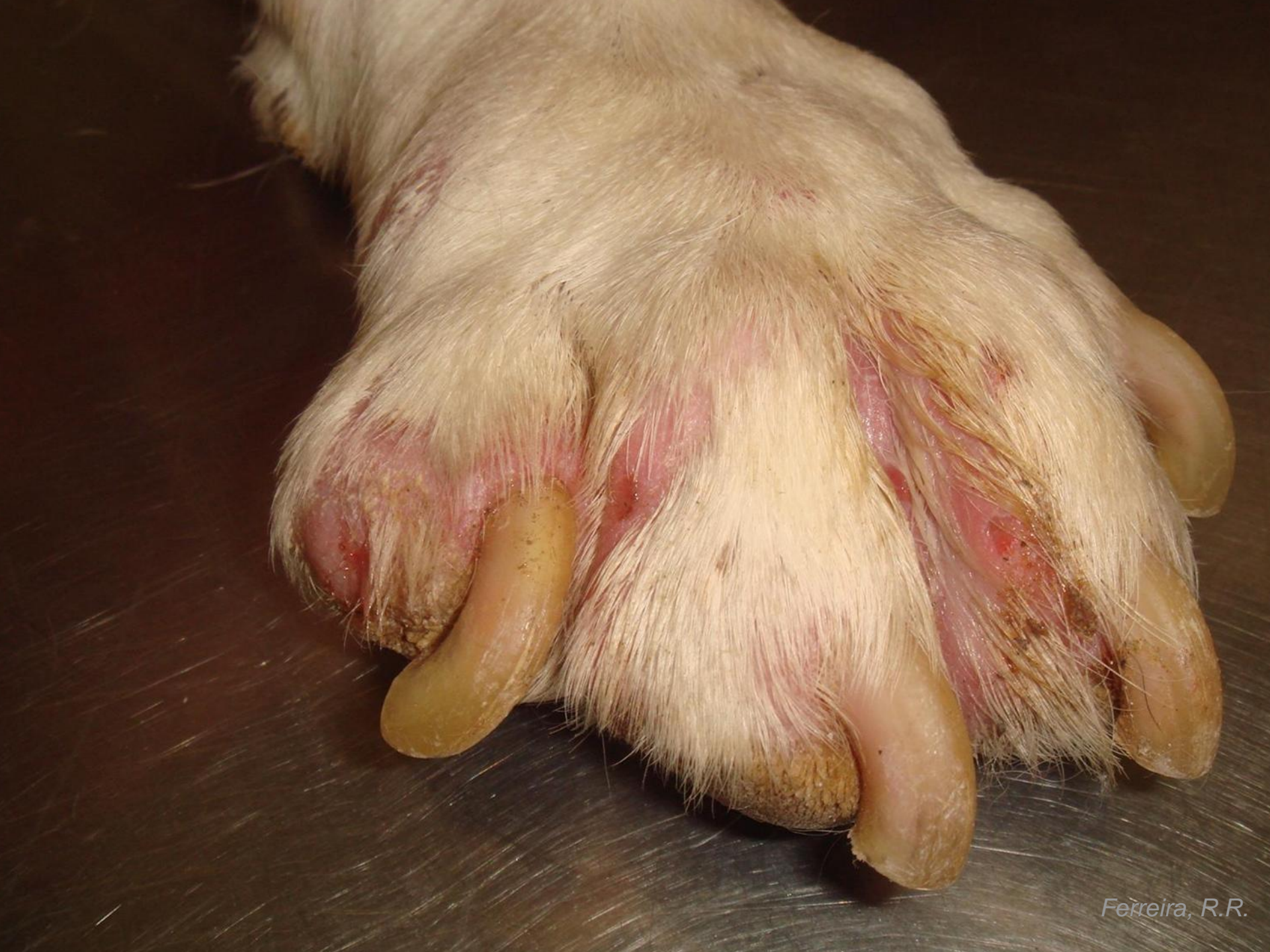


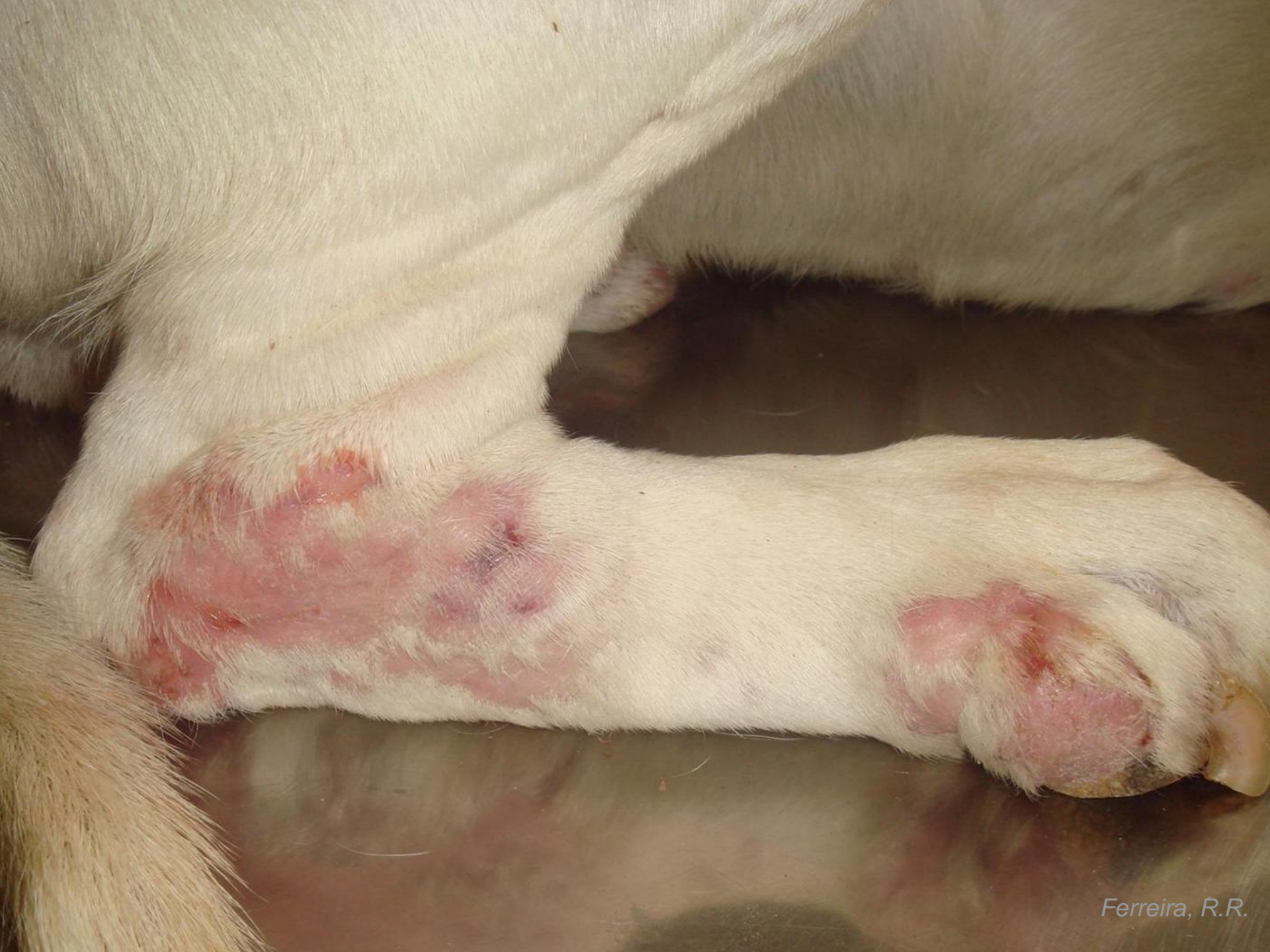




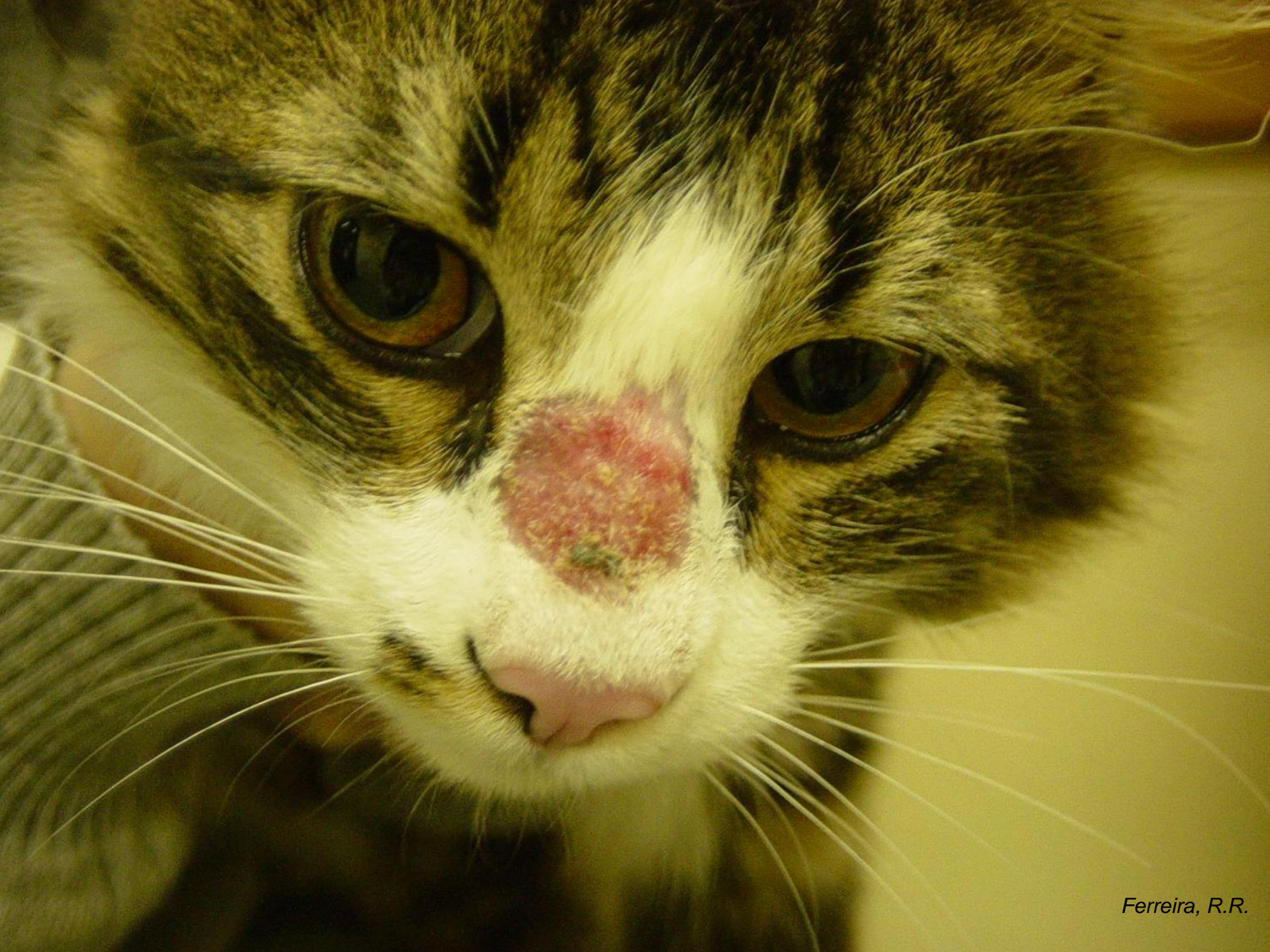


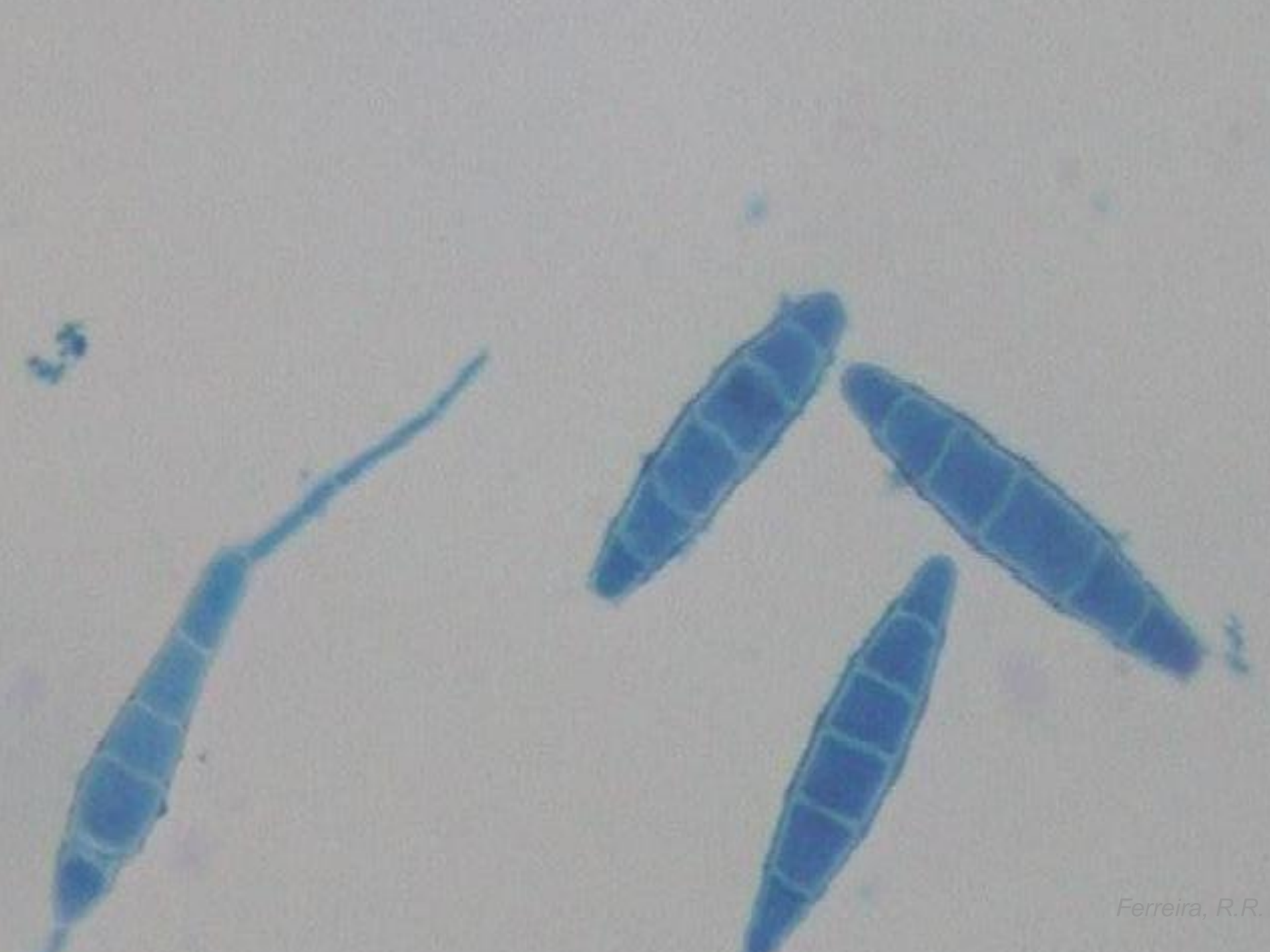
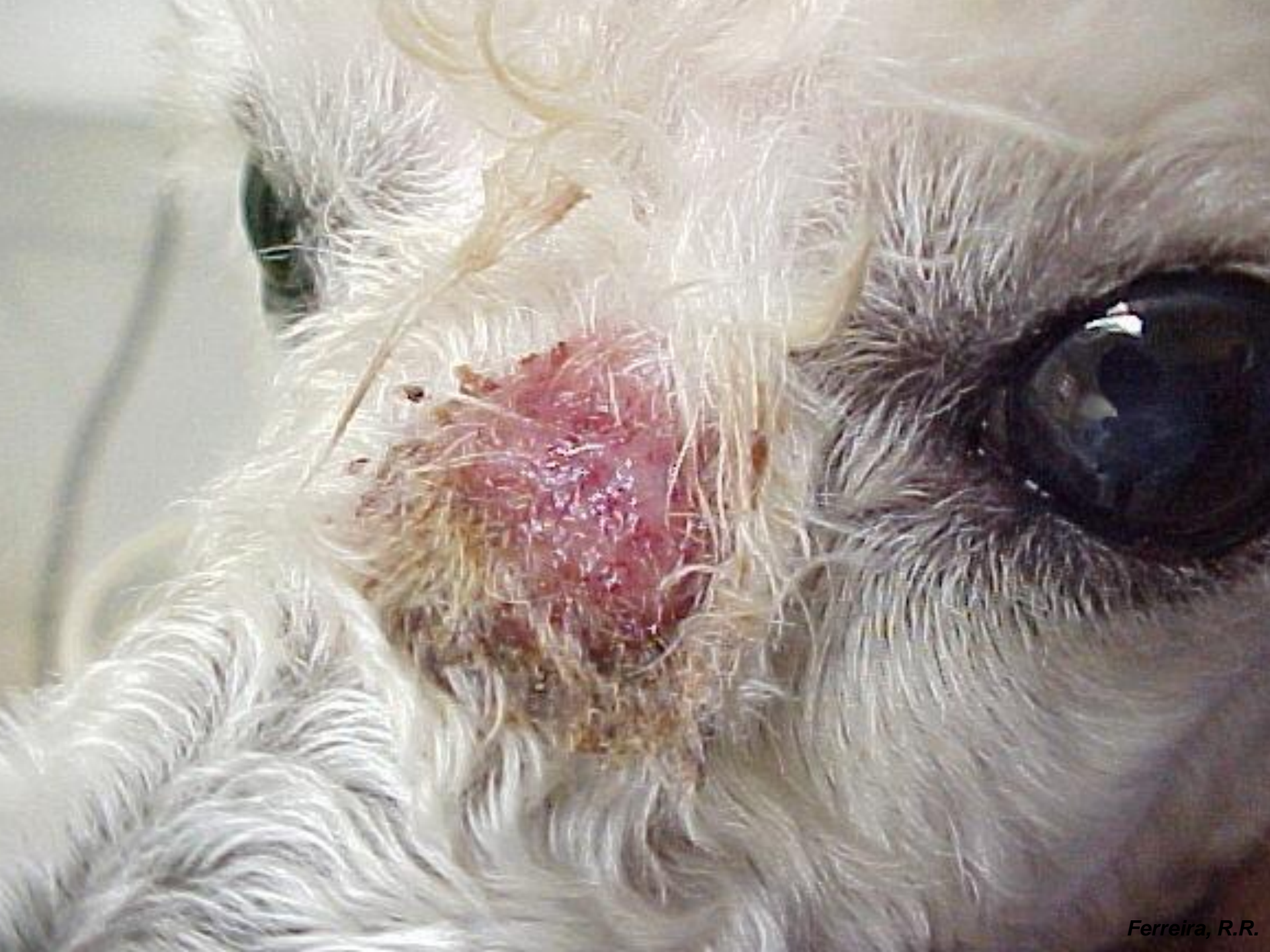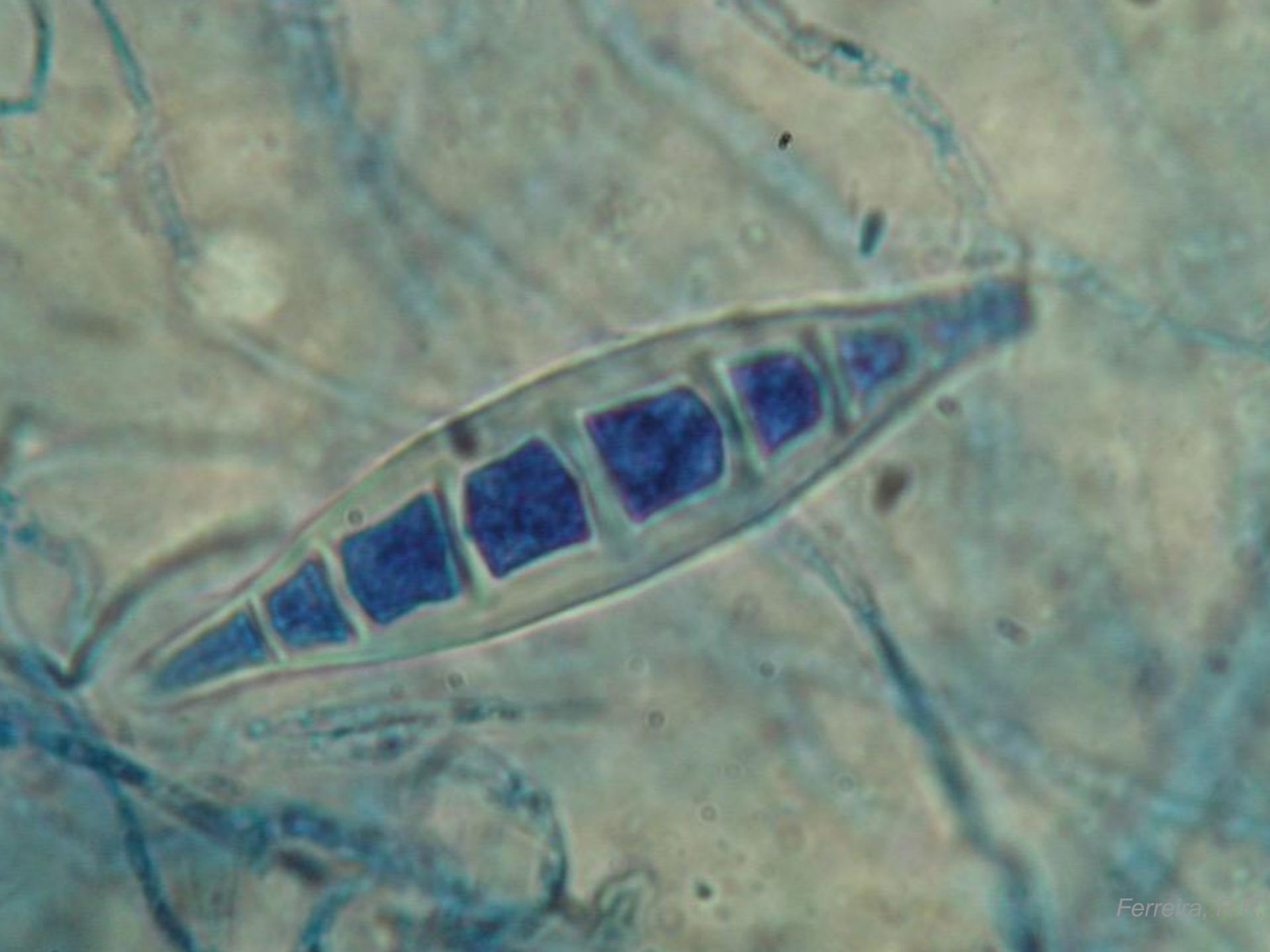DERMATOSES INFECCIOSAS

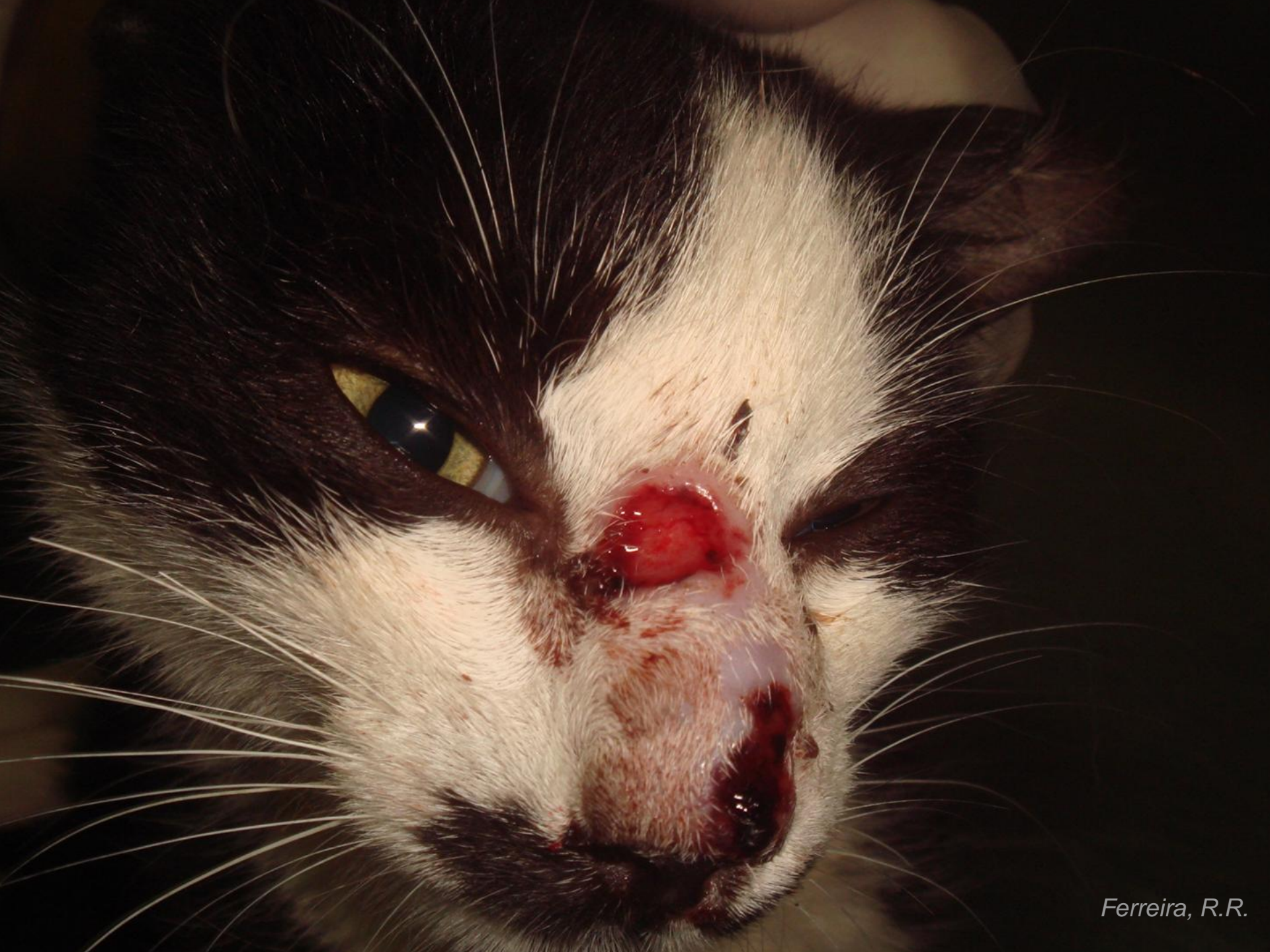

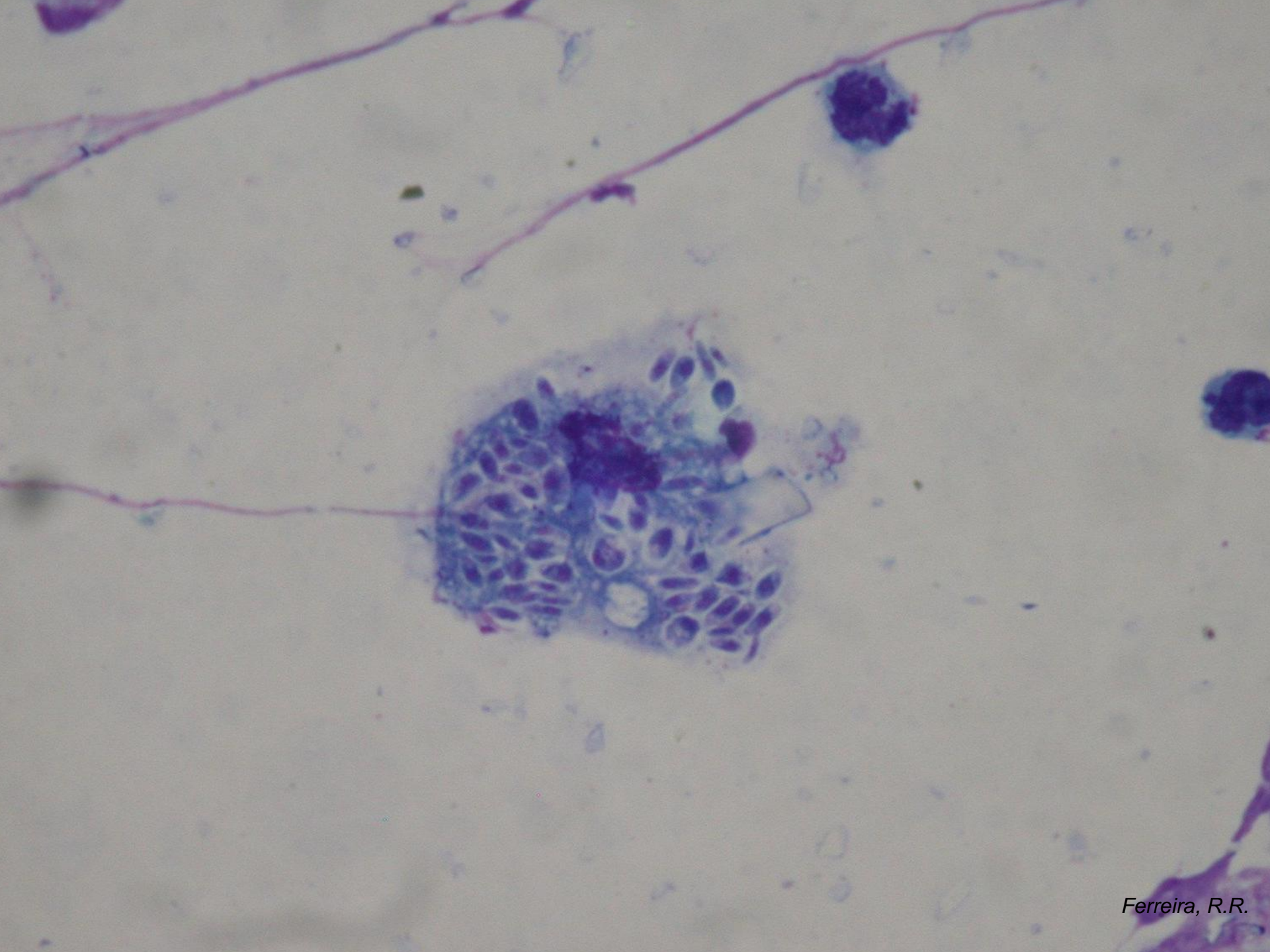



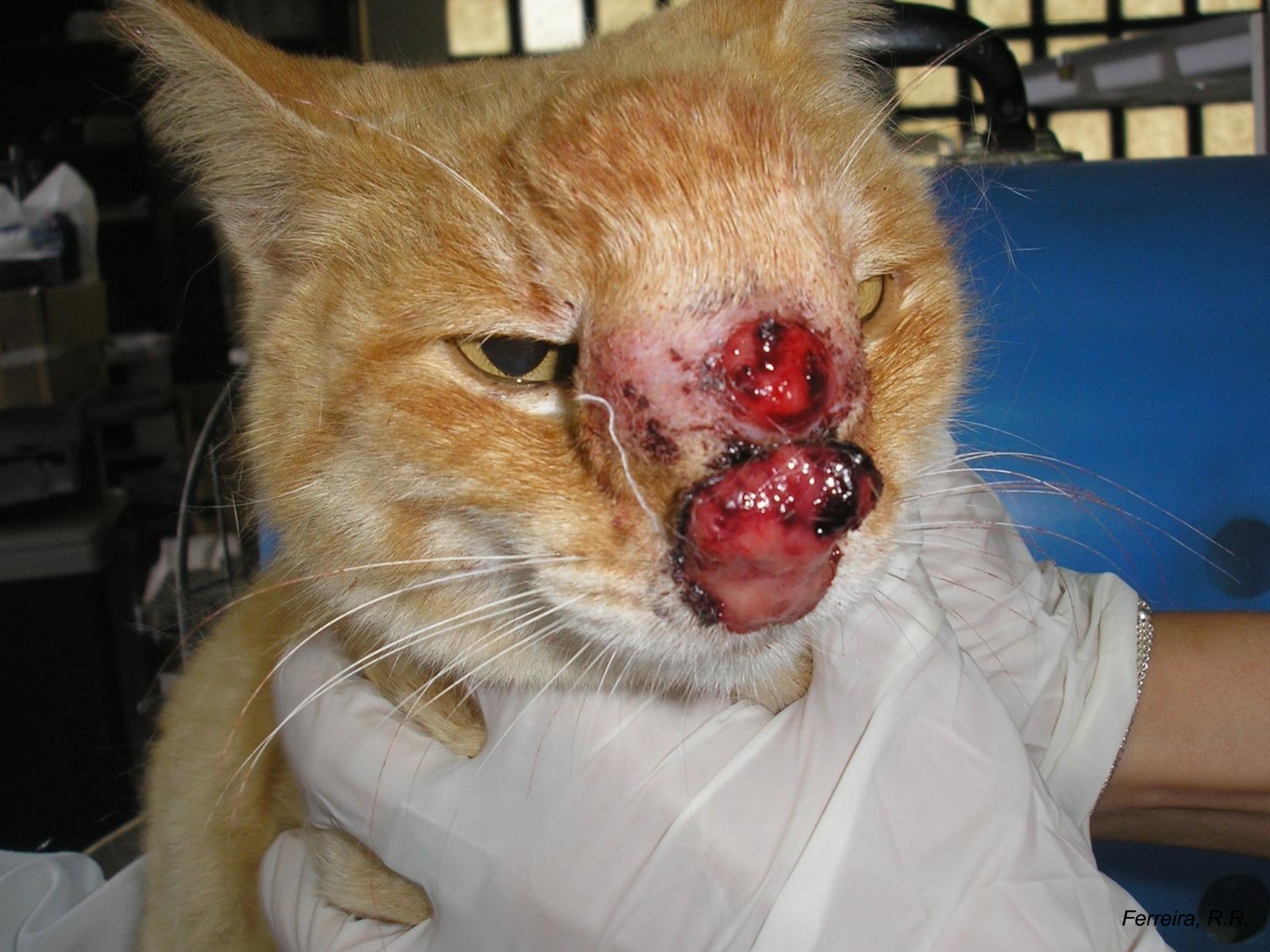
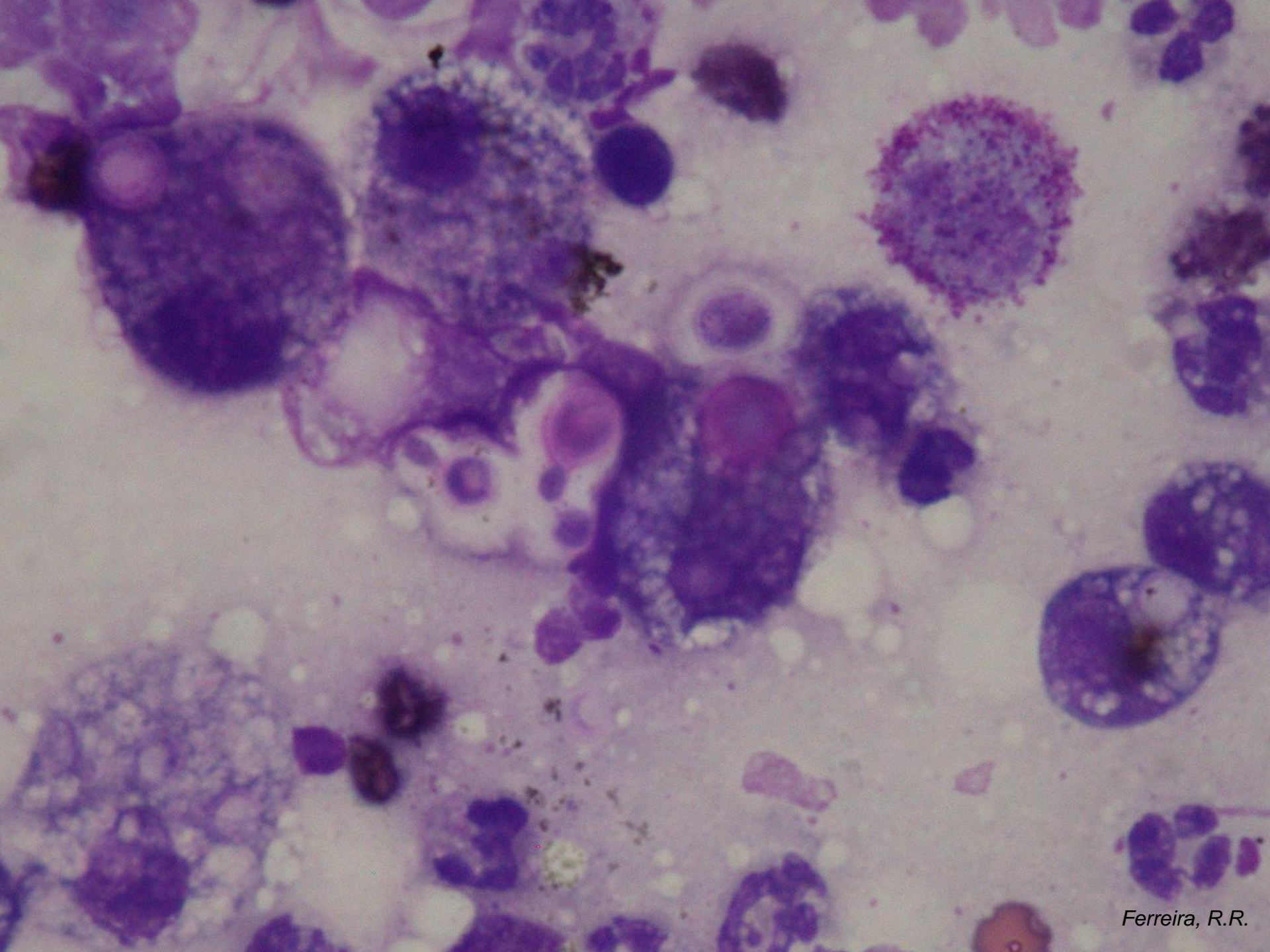




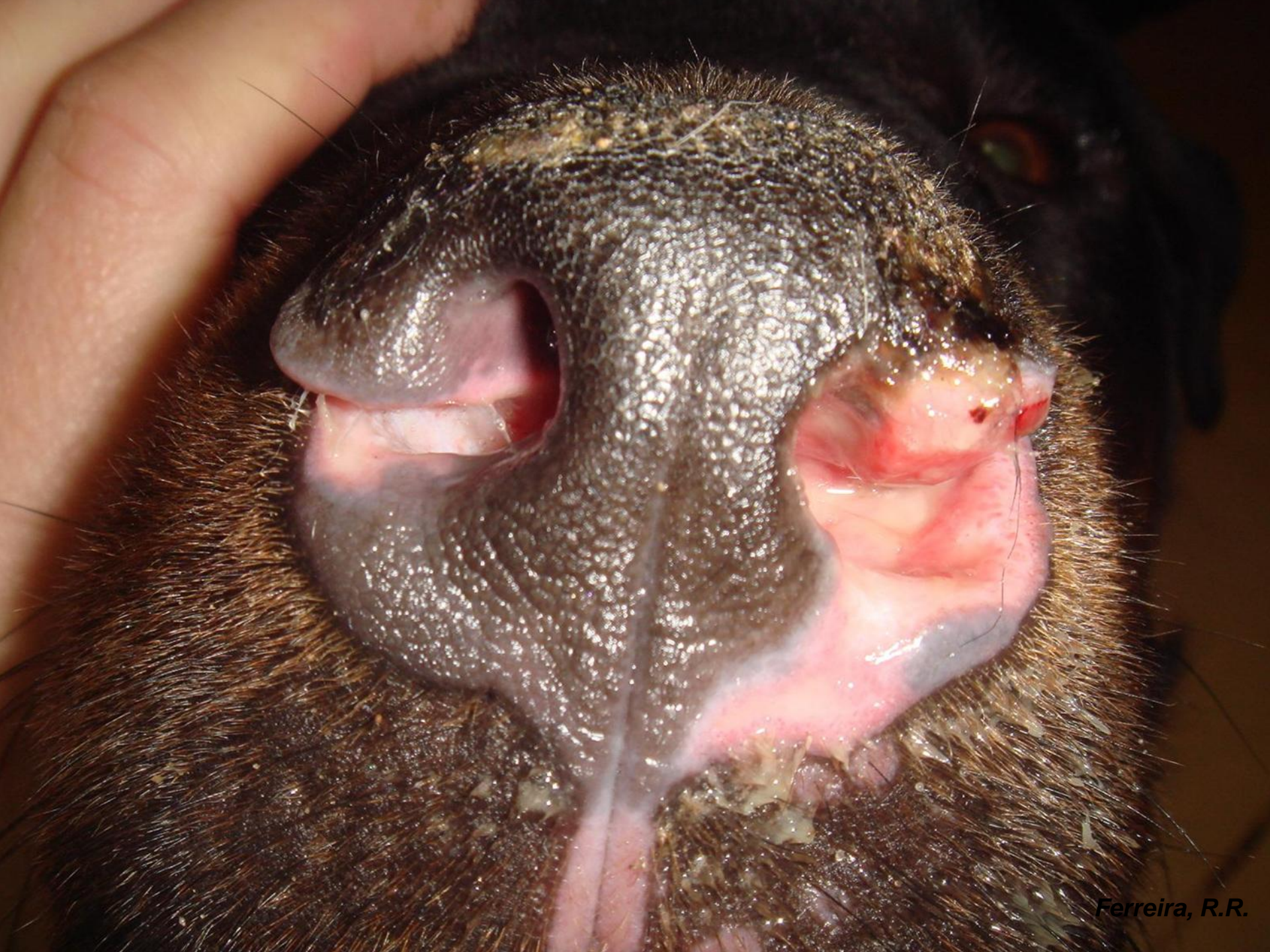


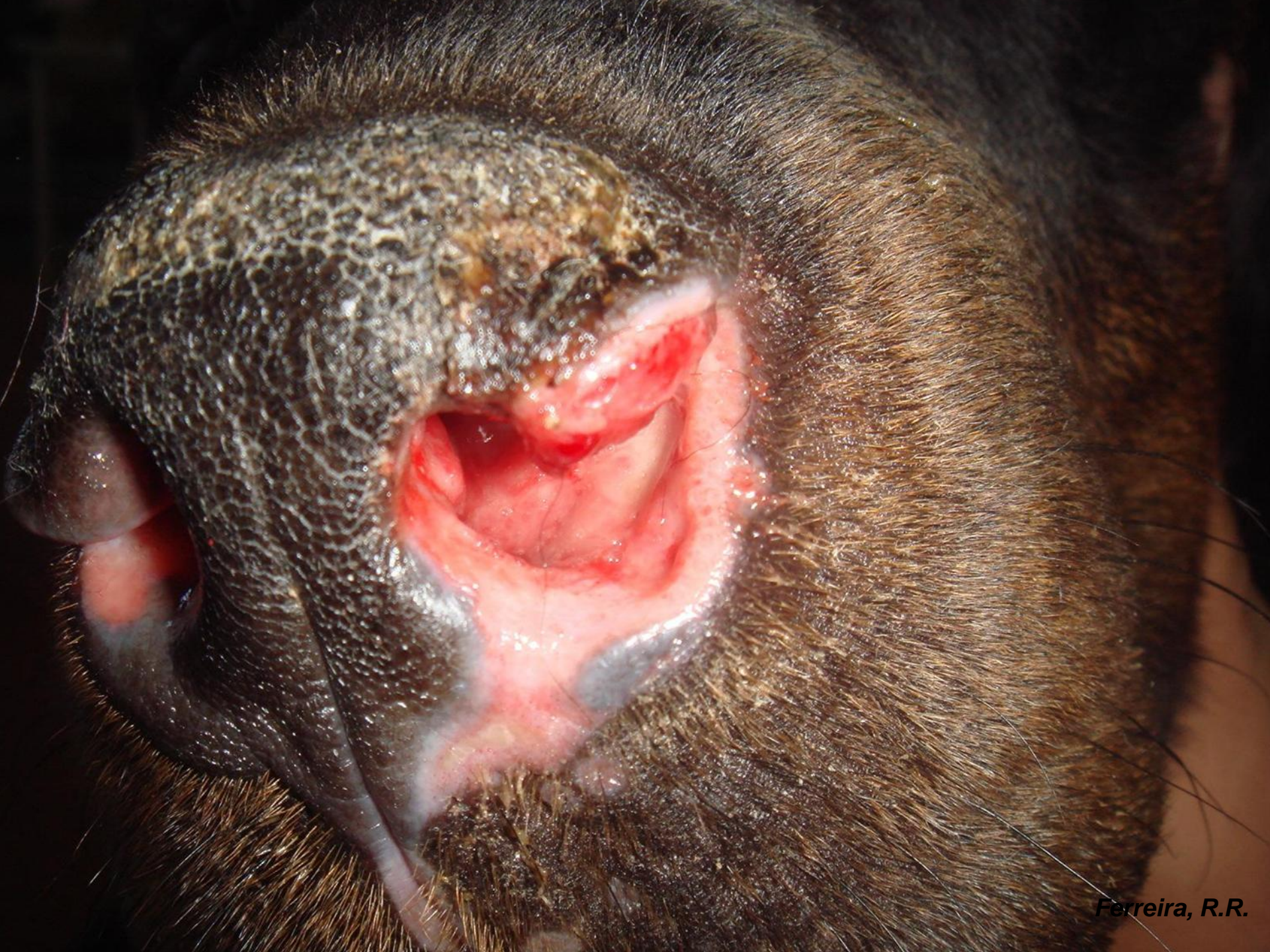
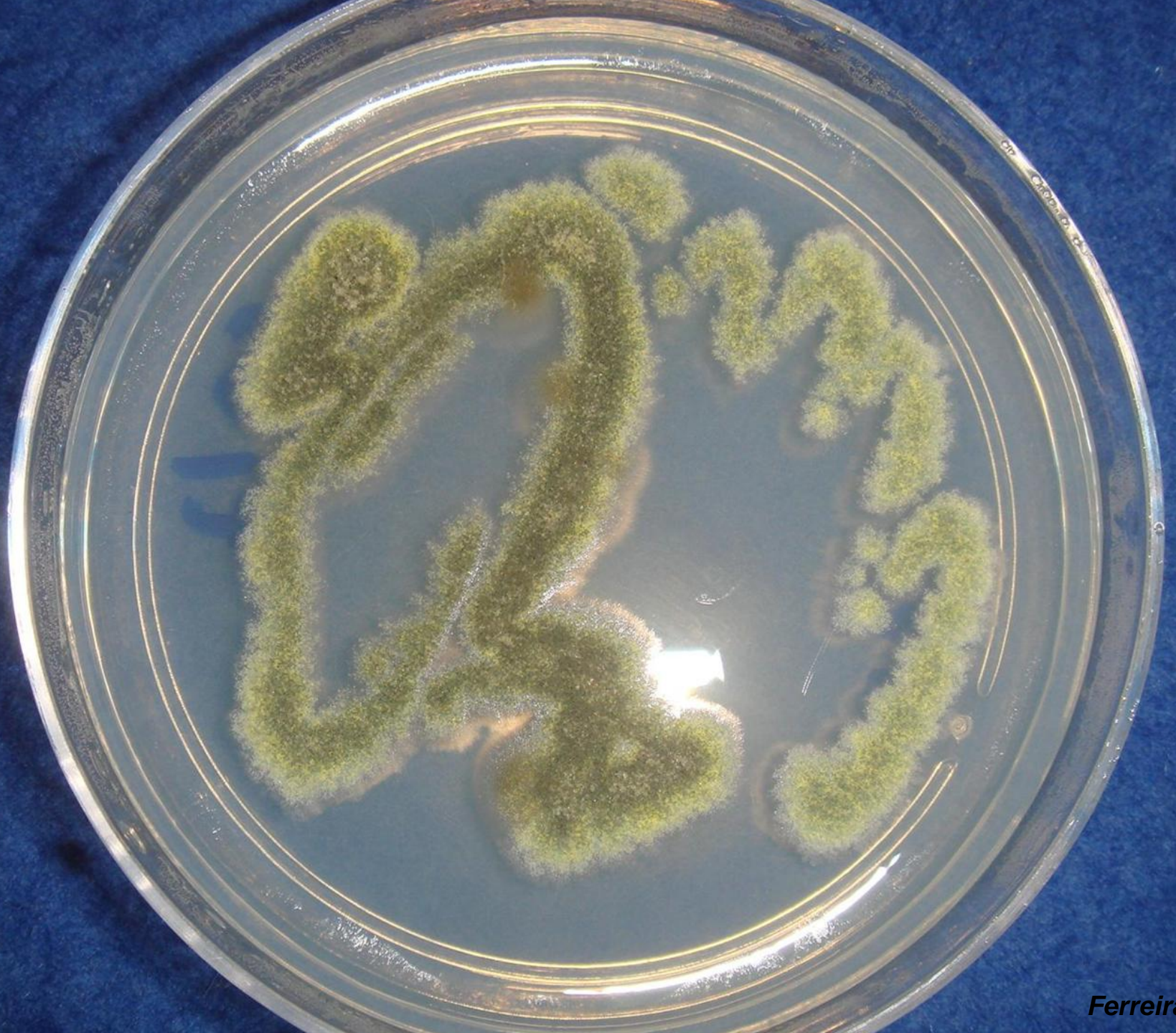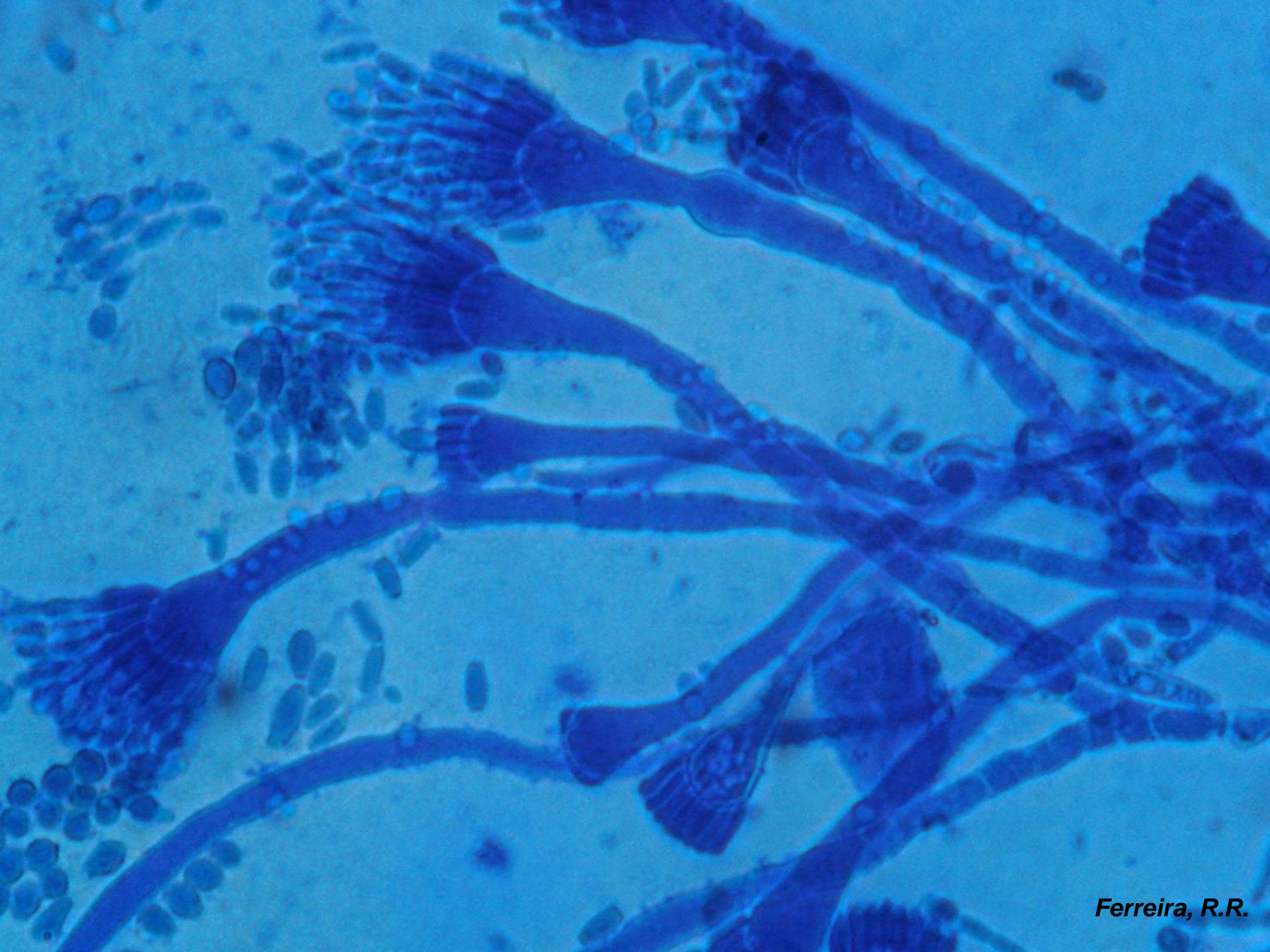




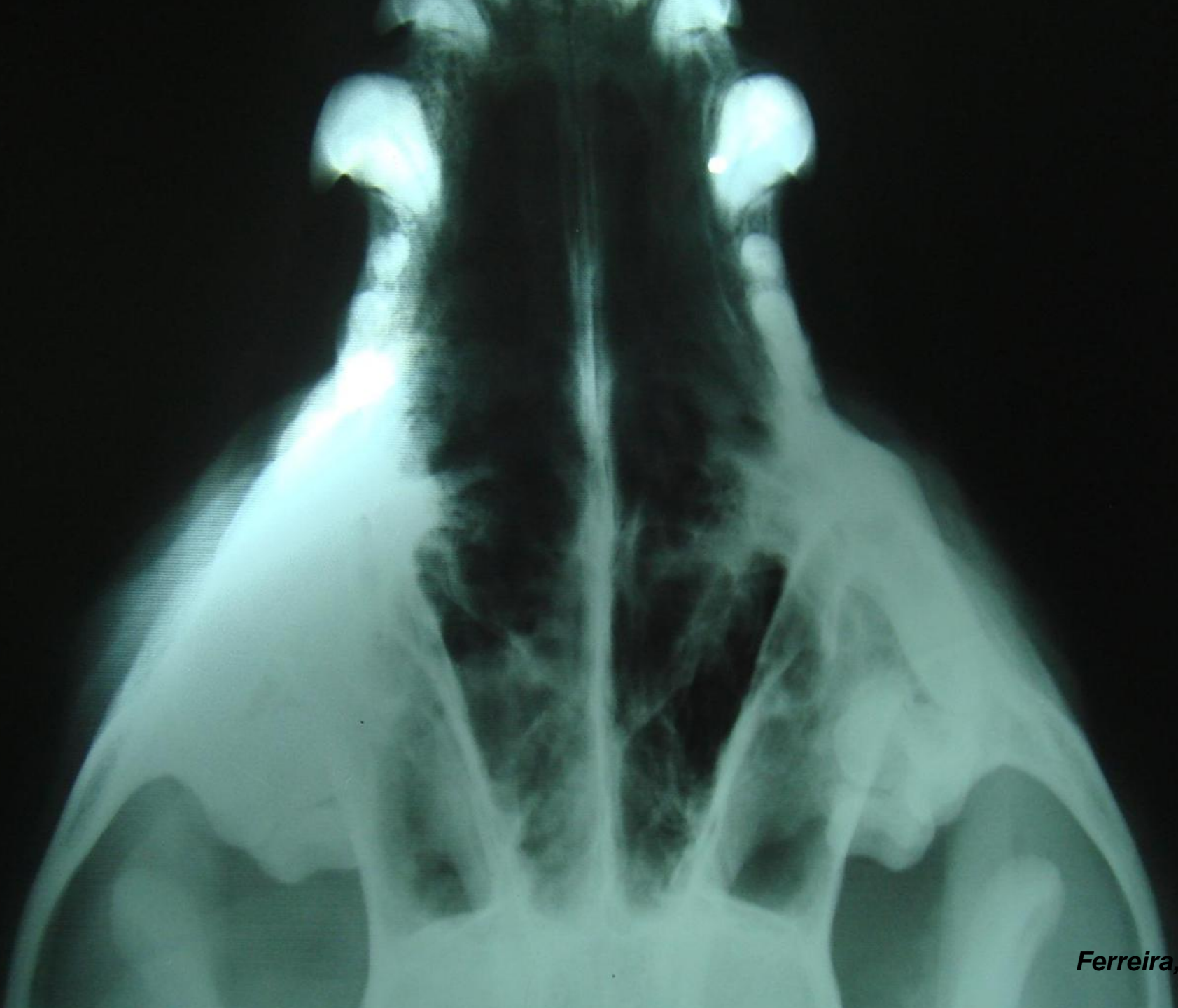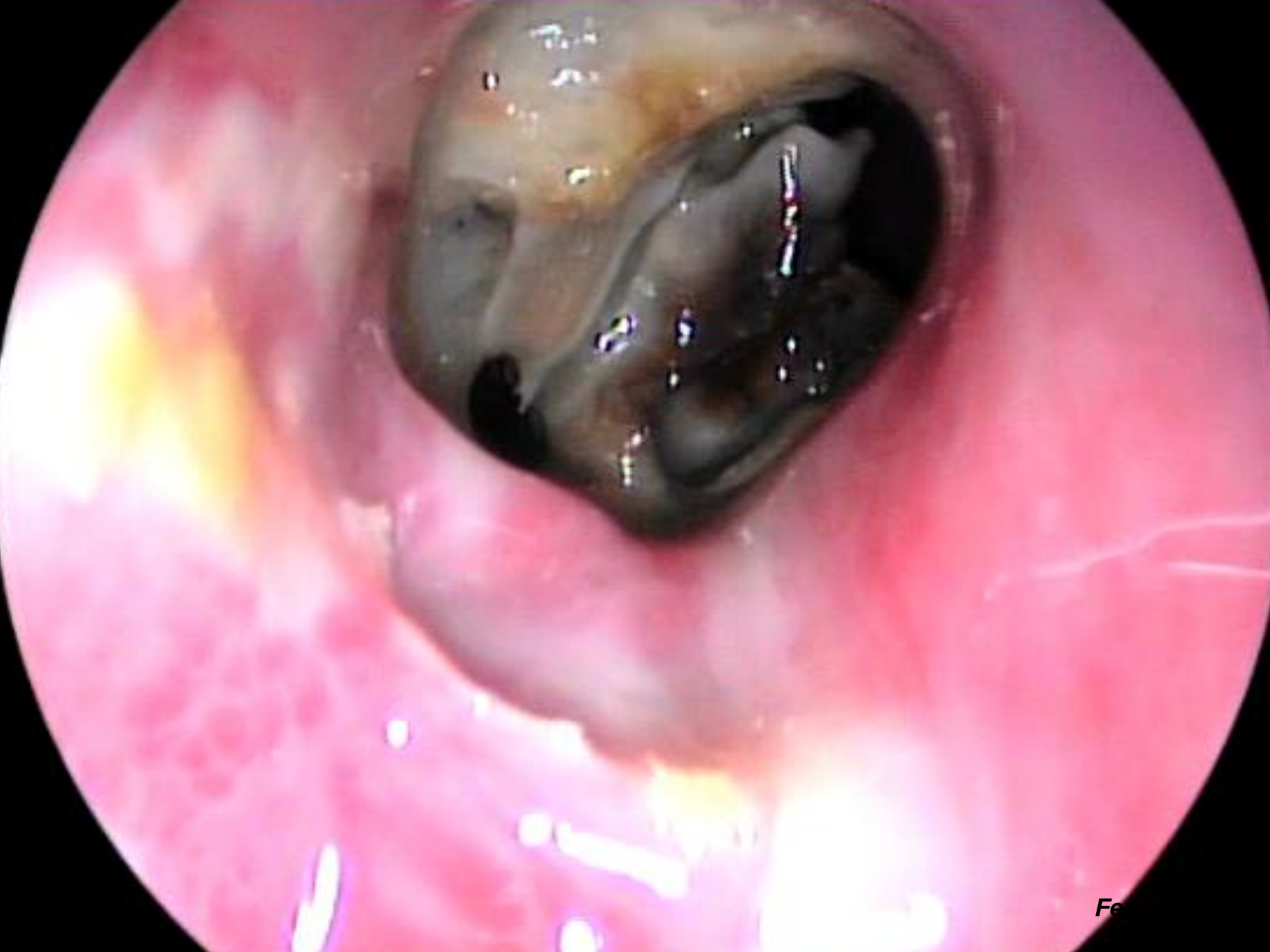




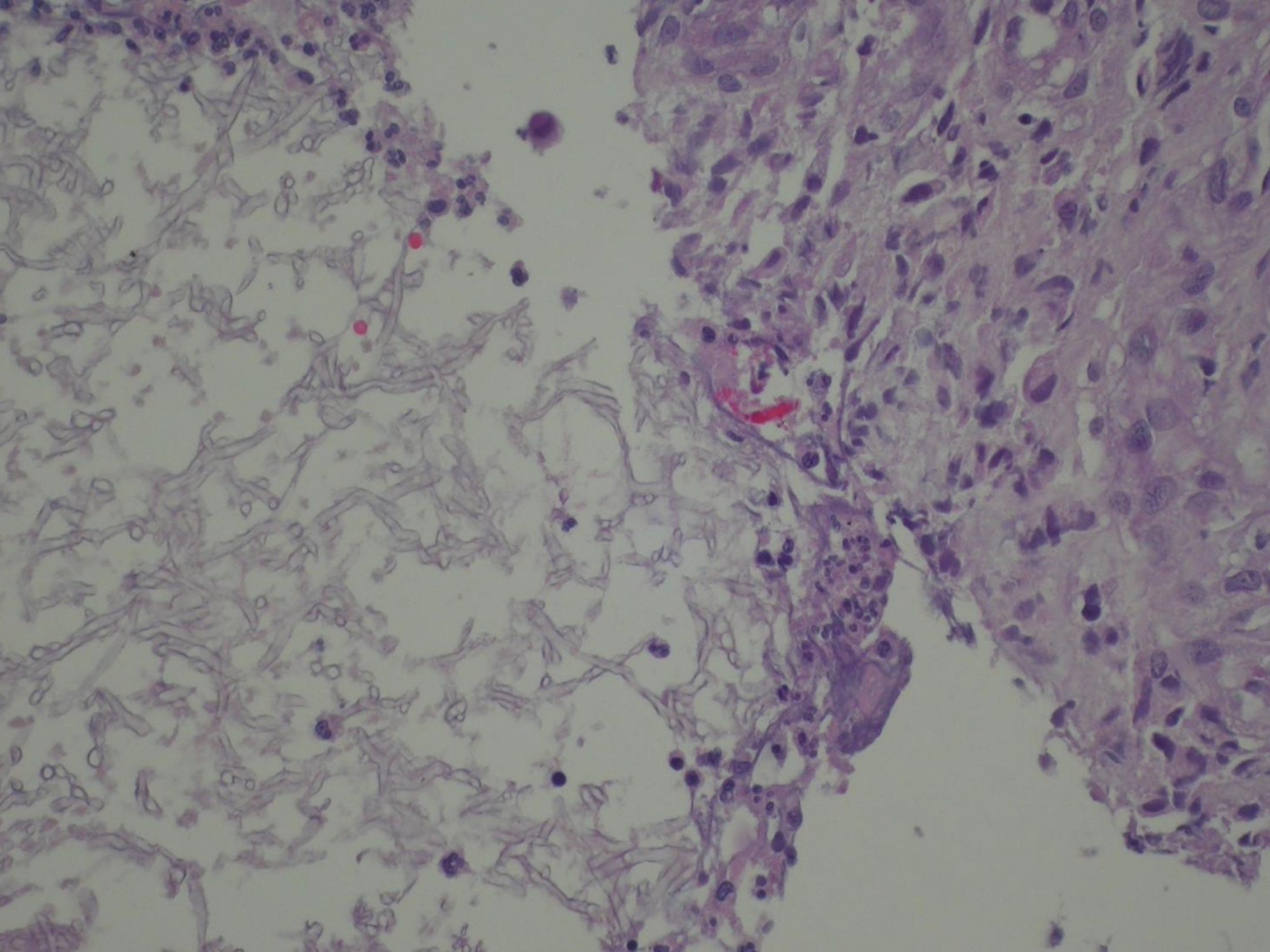








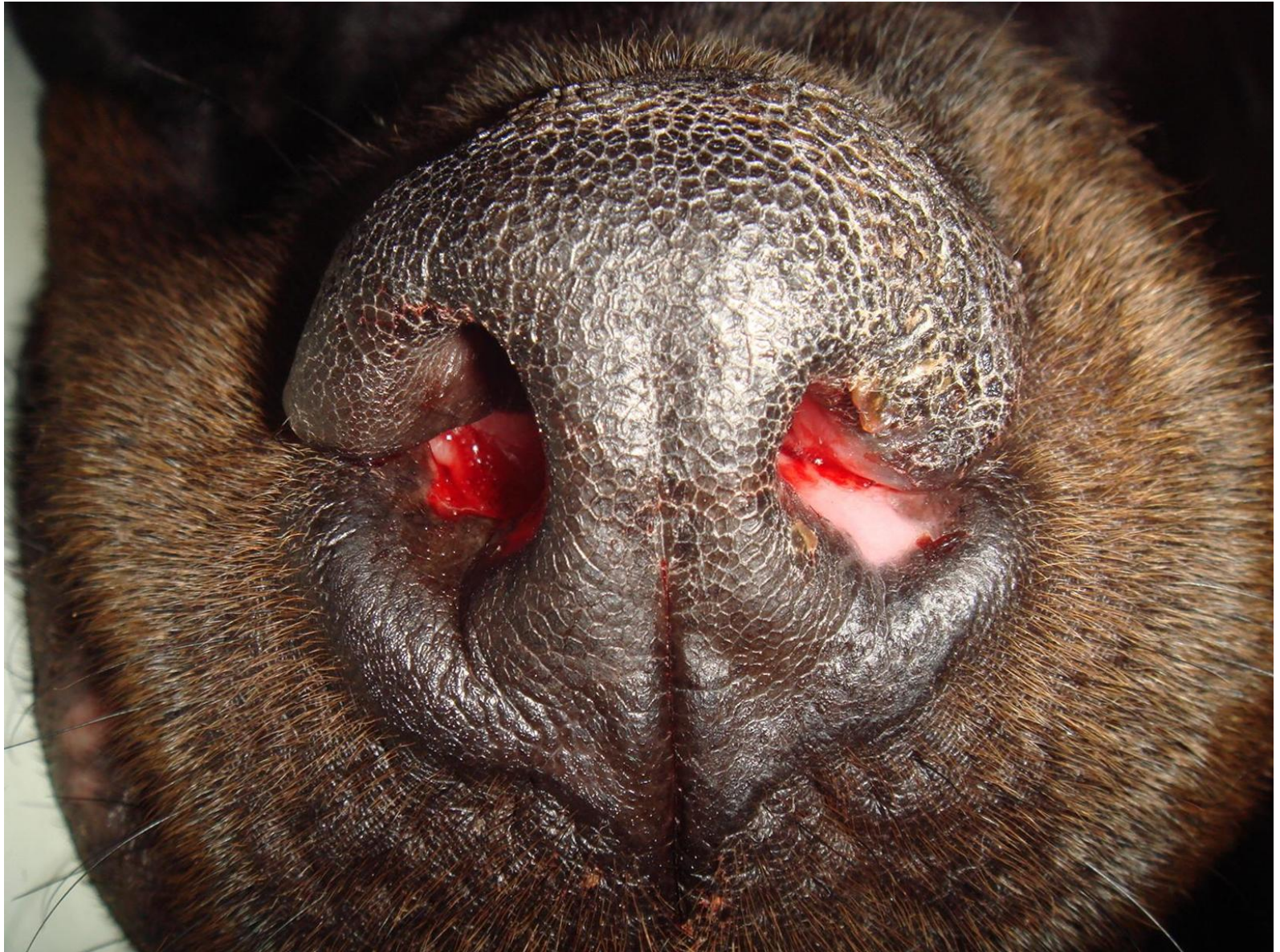


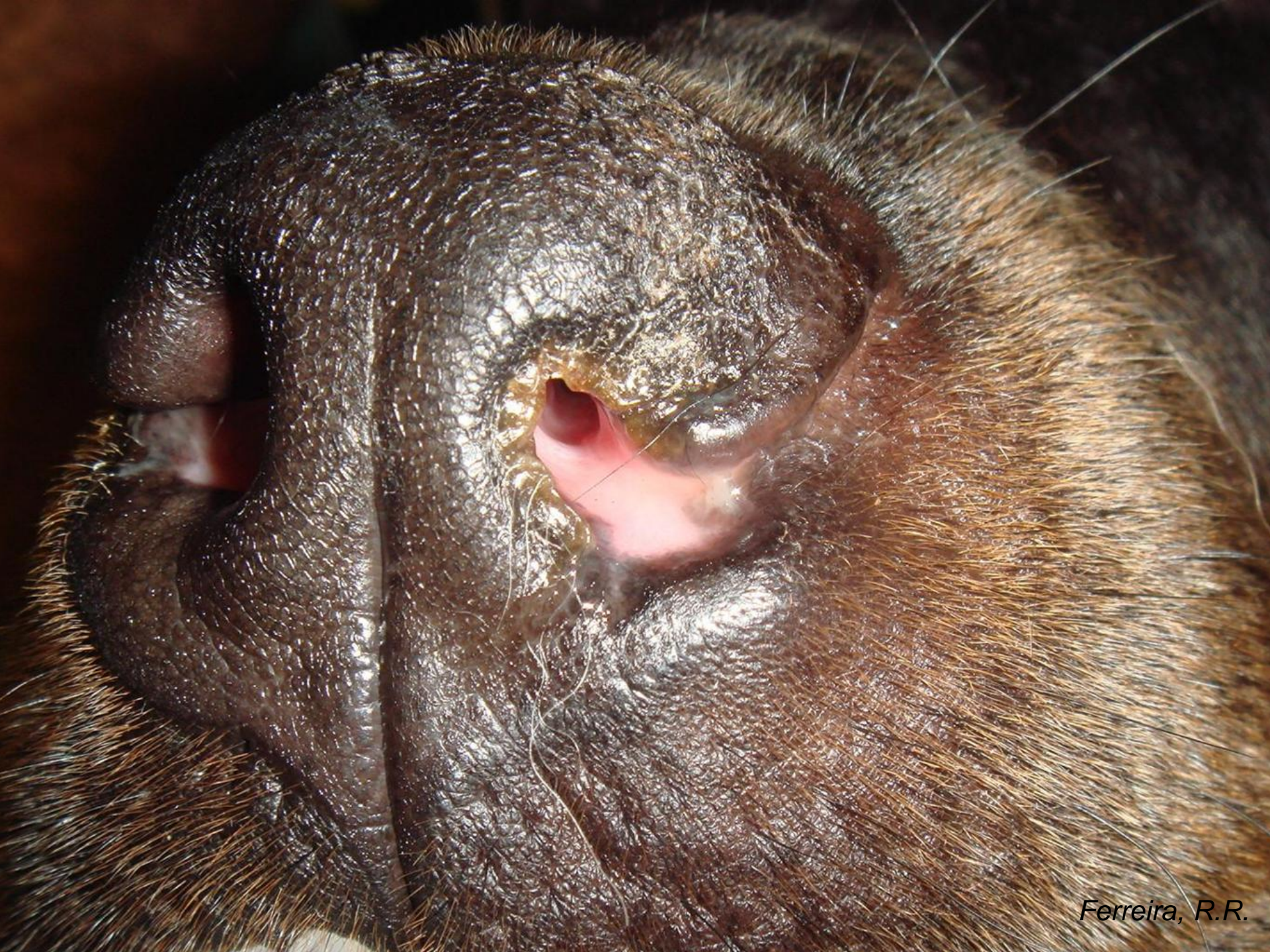


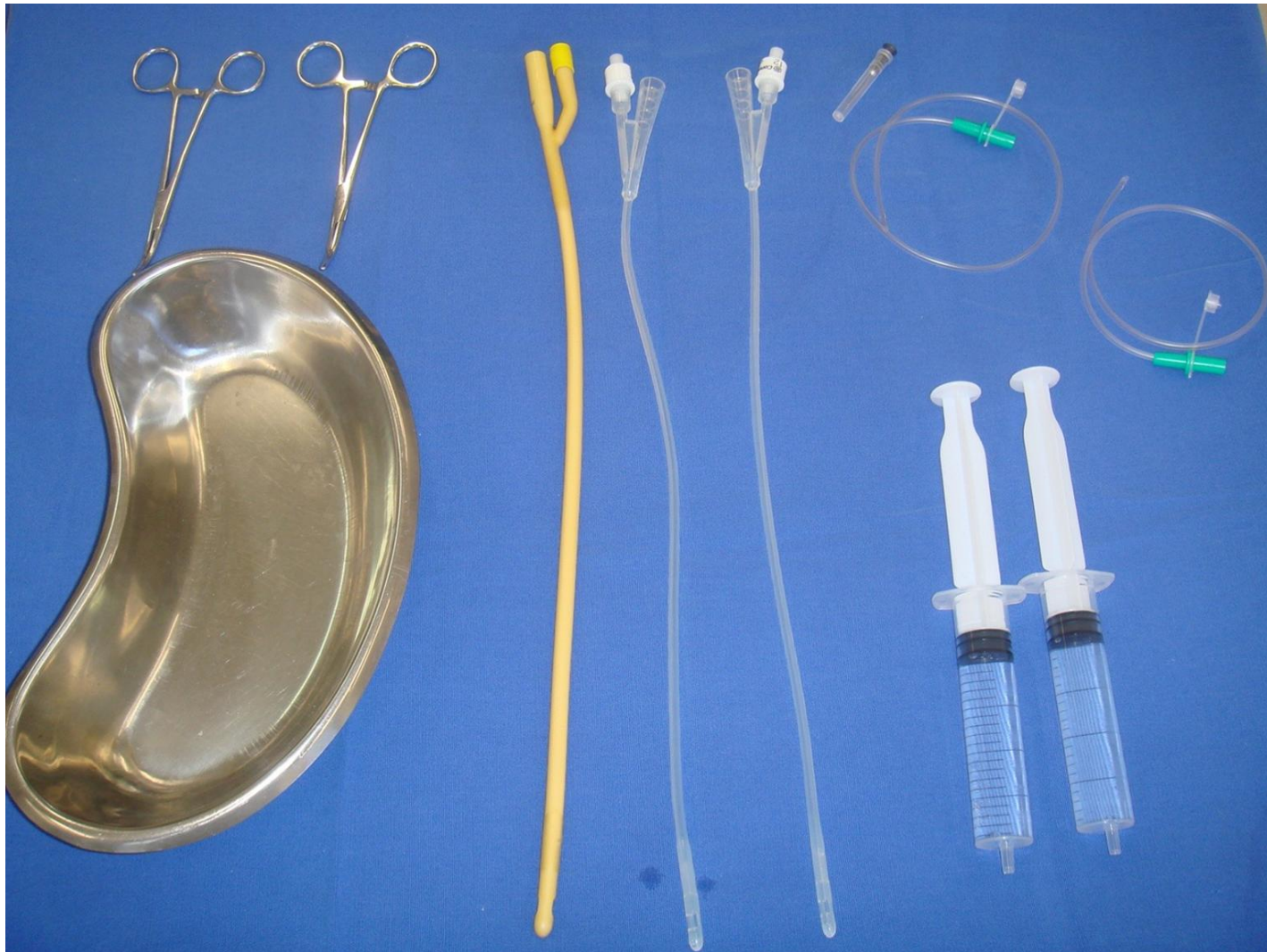


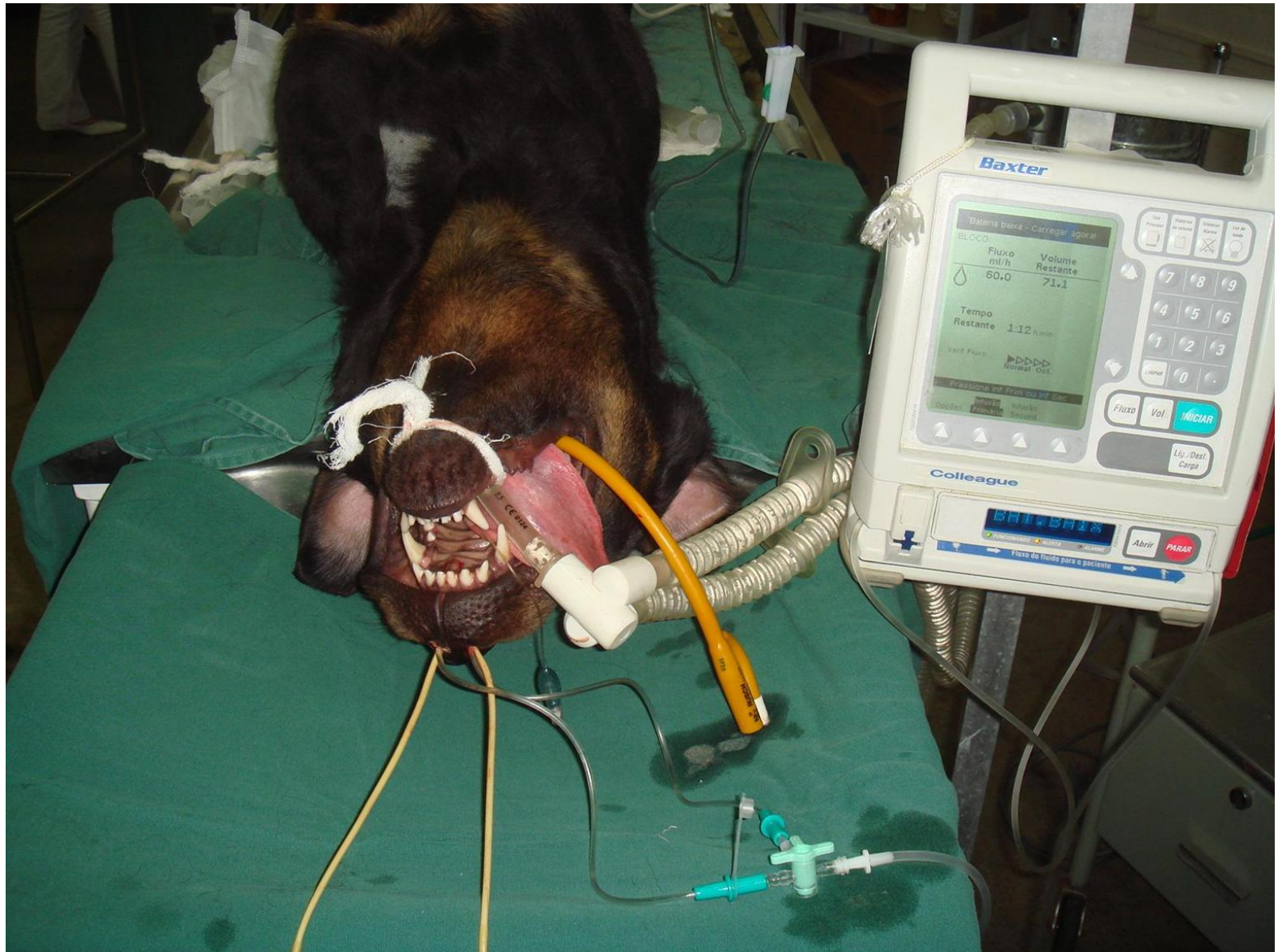


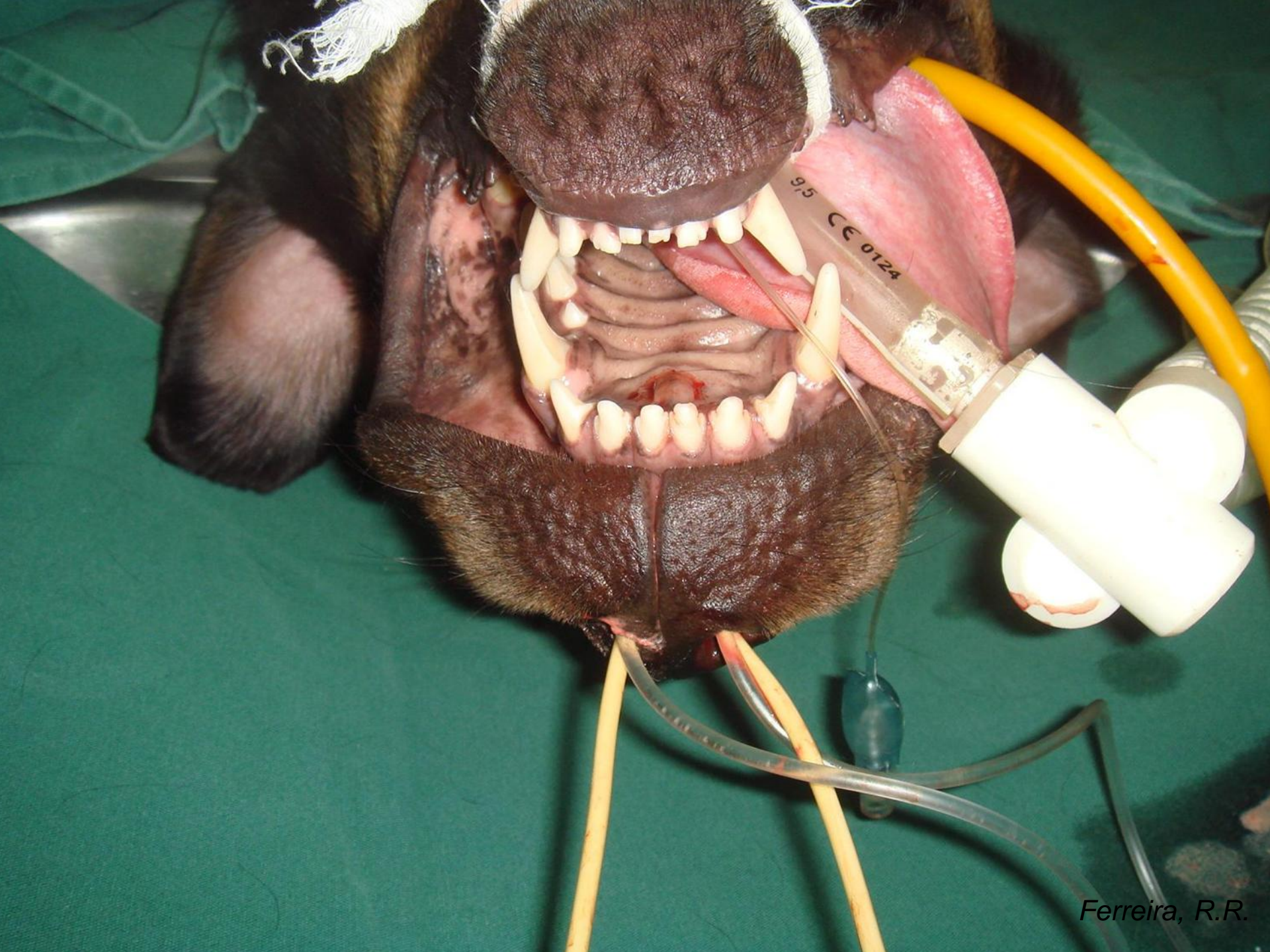


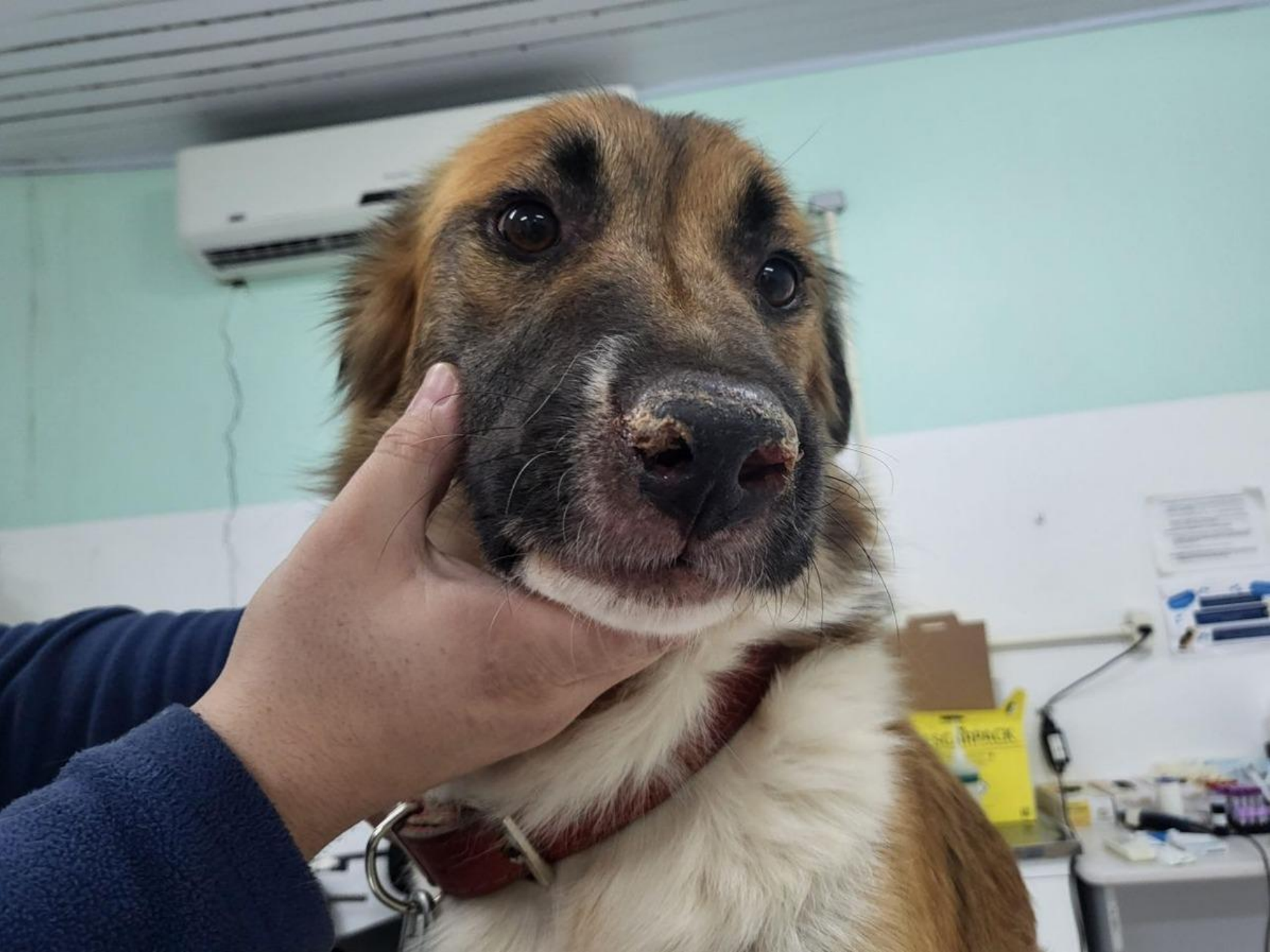






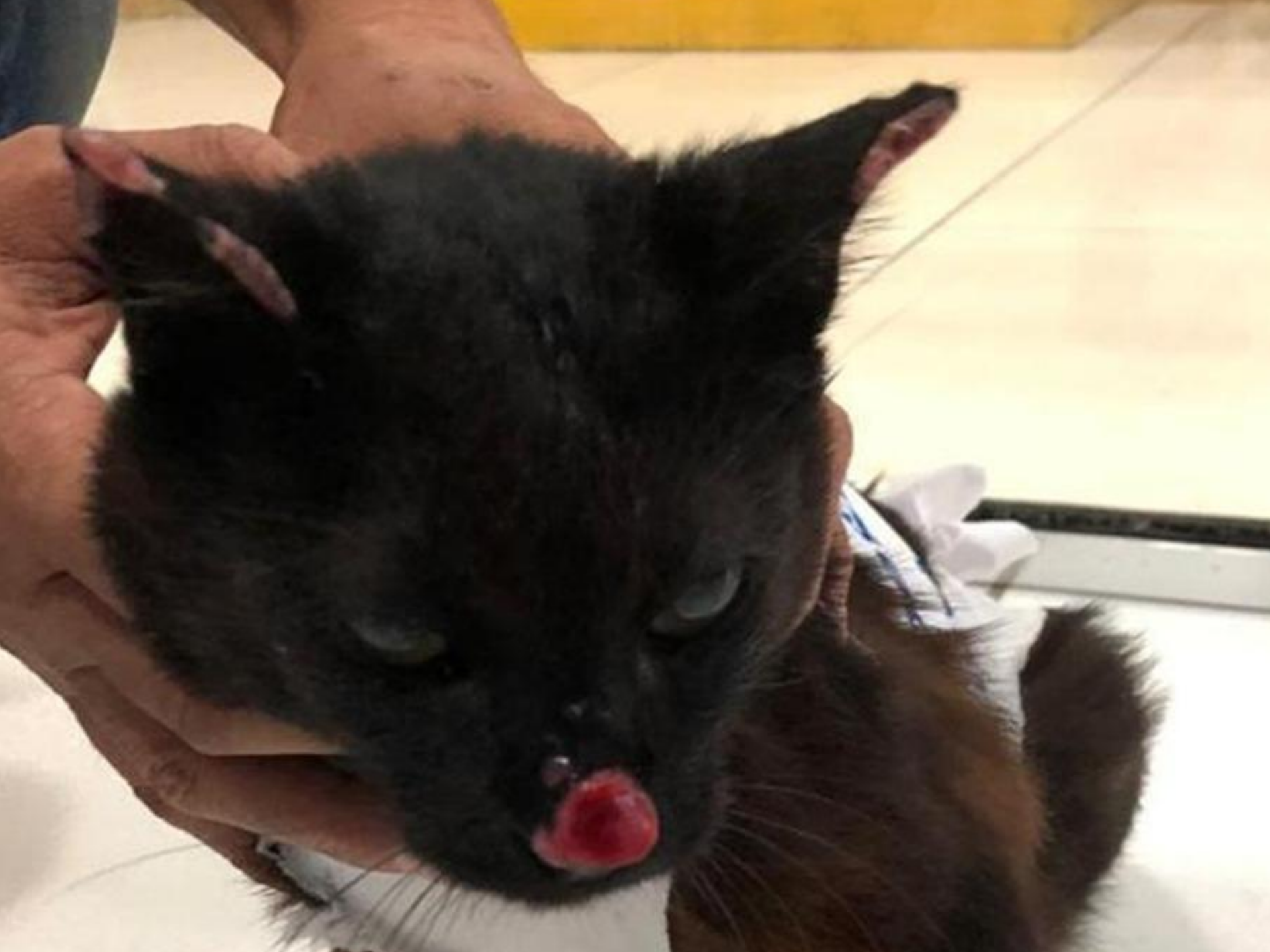


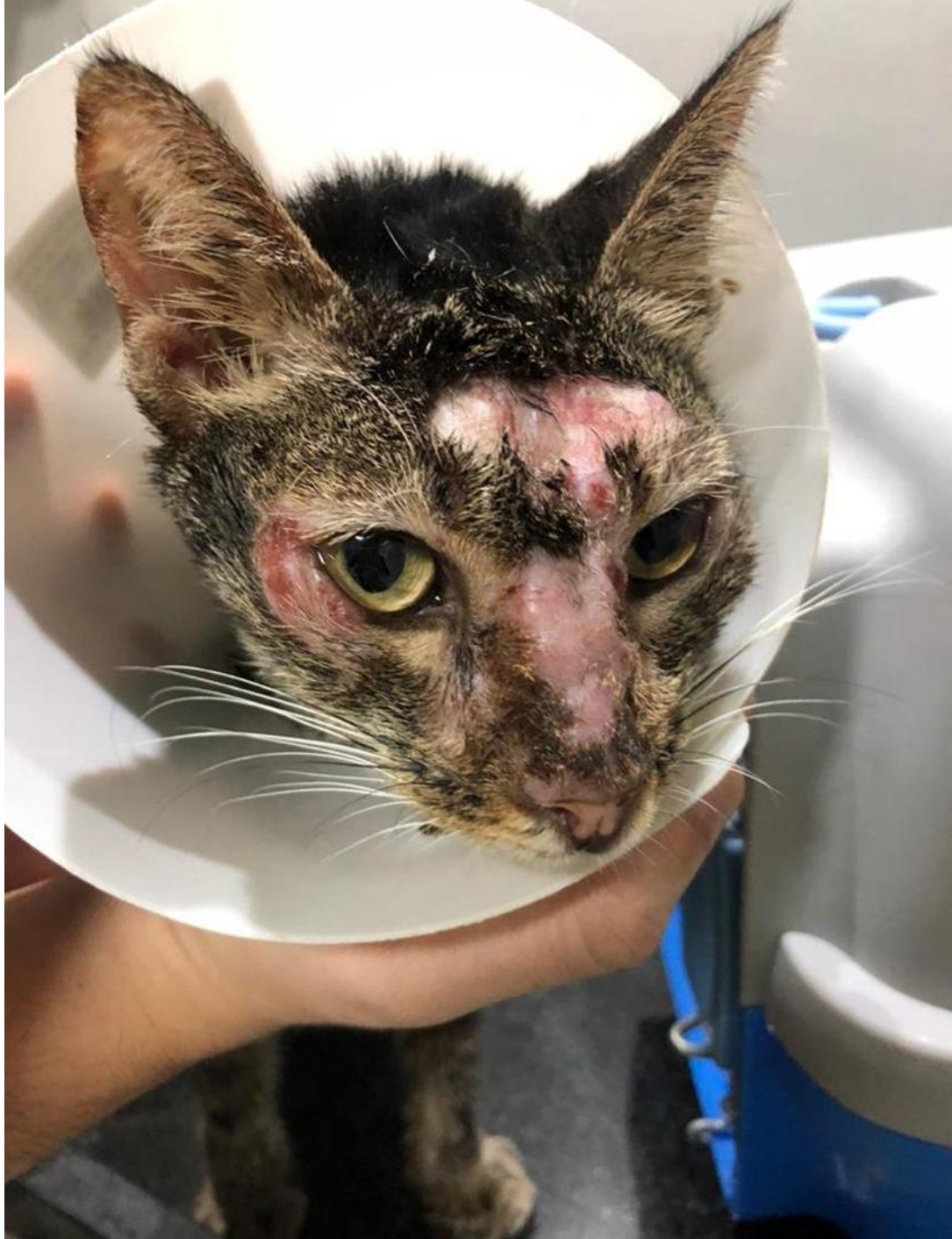

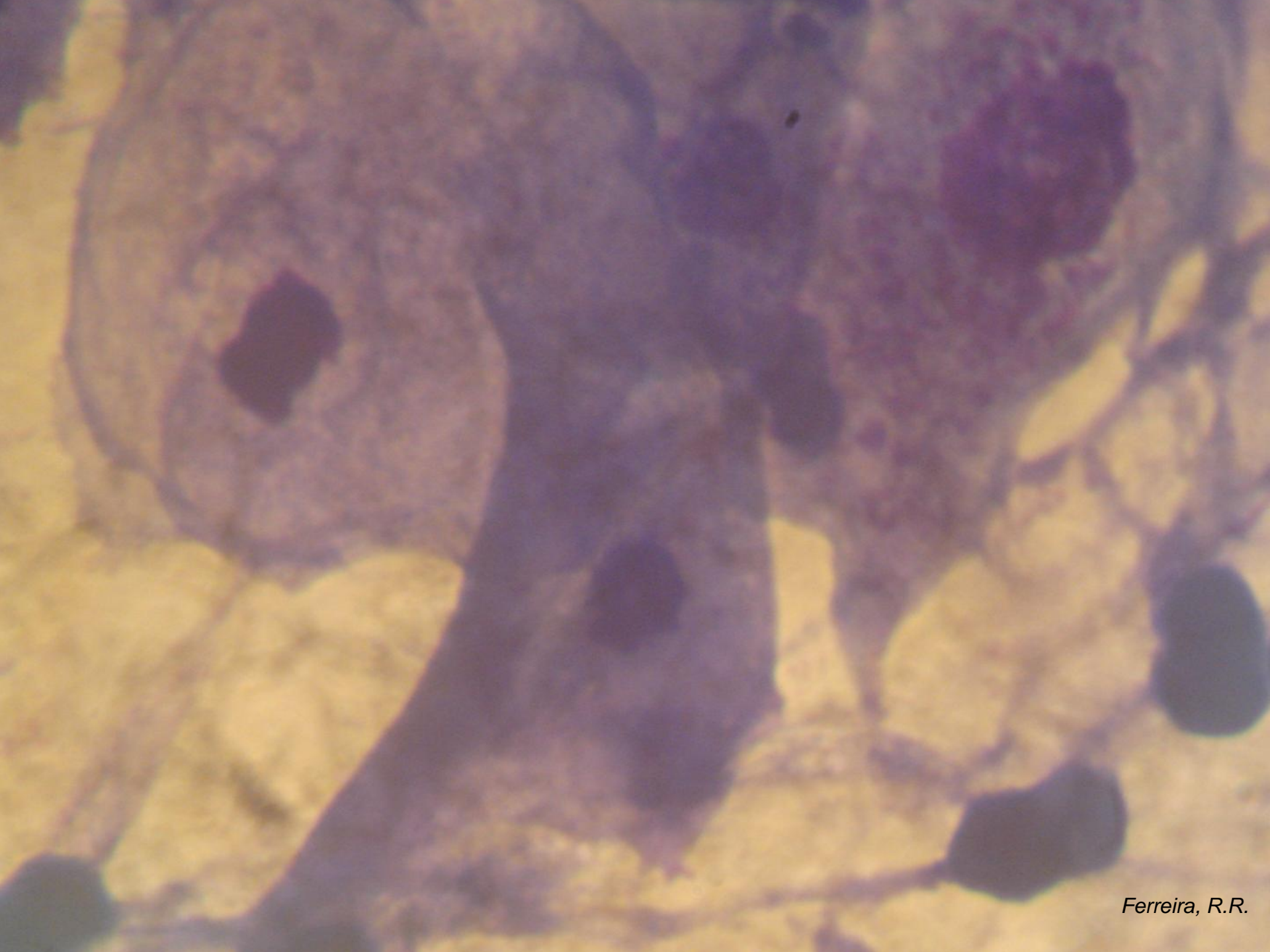
DERMATOVET
CURSOS

CRK202

DOENÇAS TUMORAIS

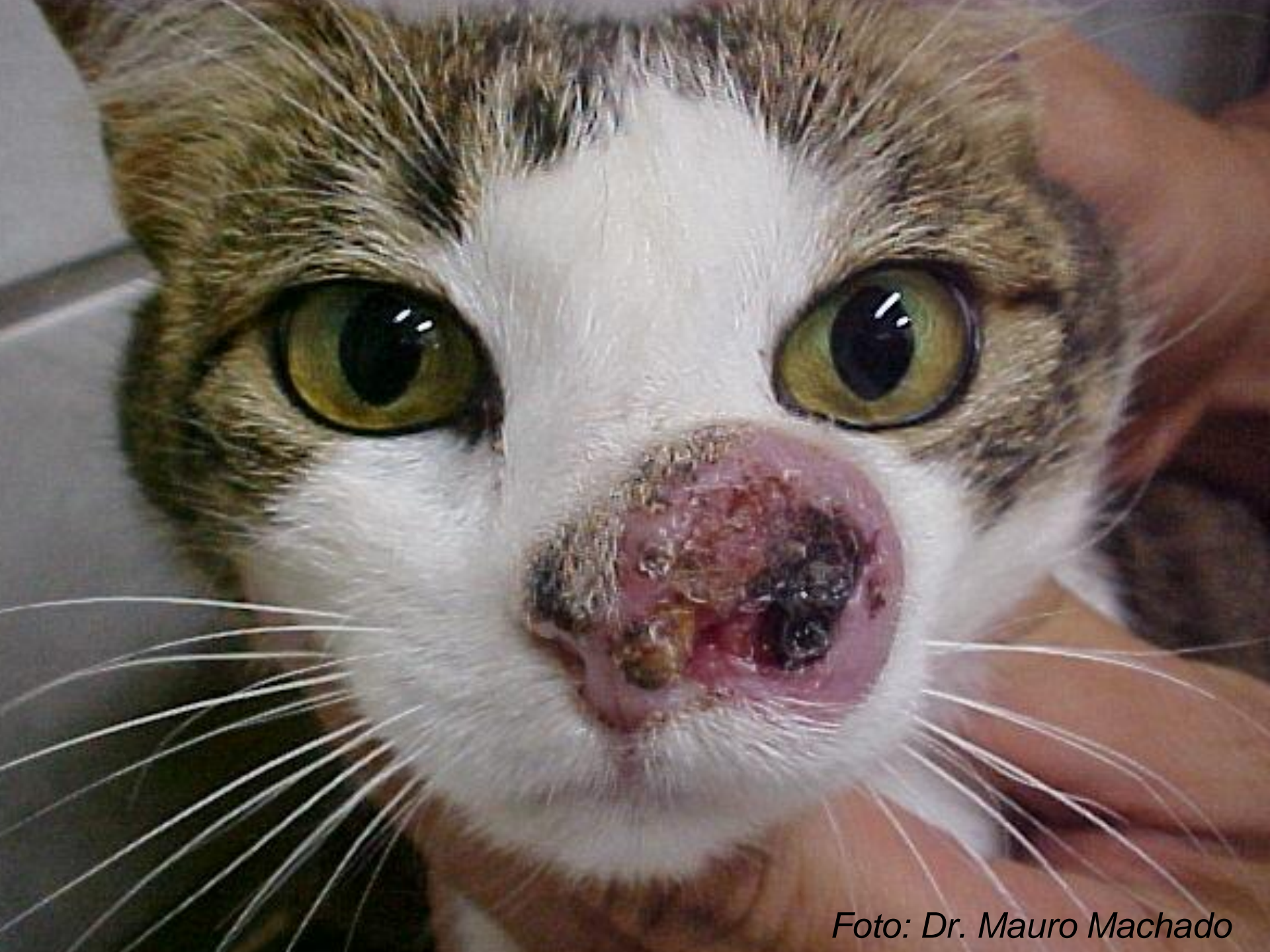

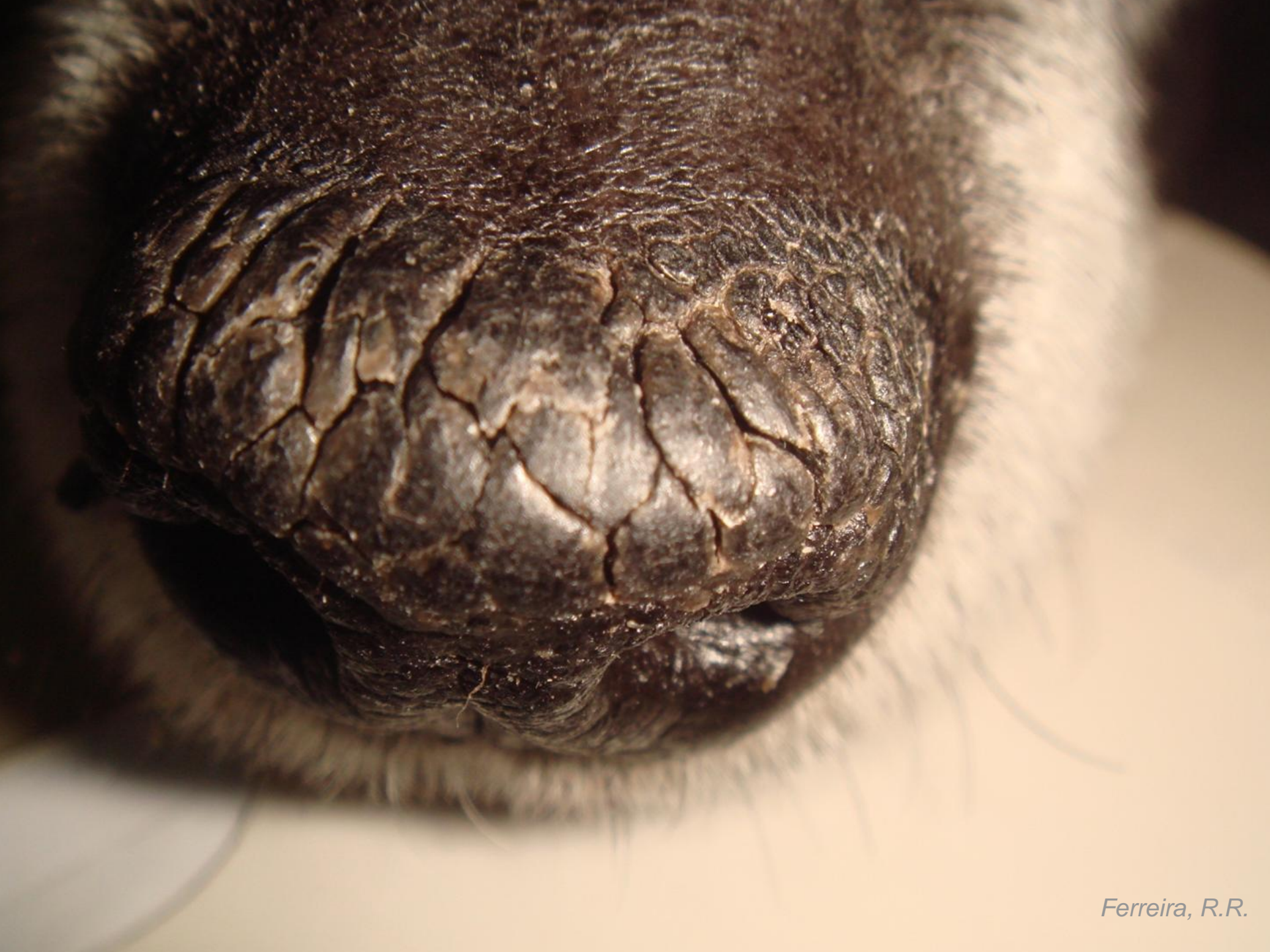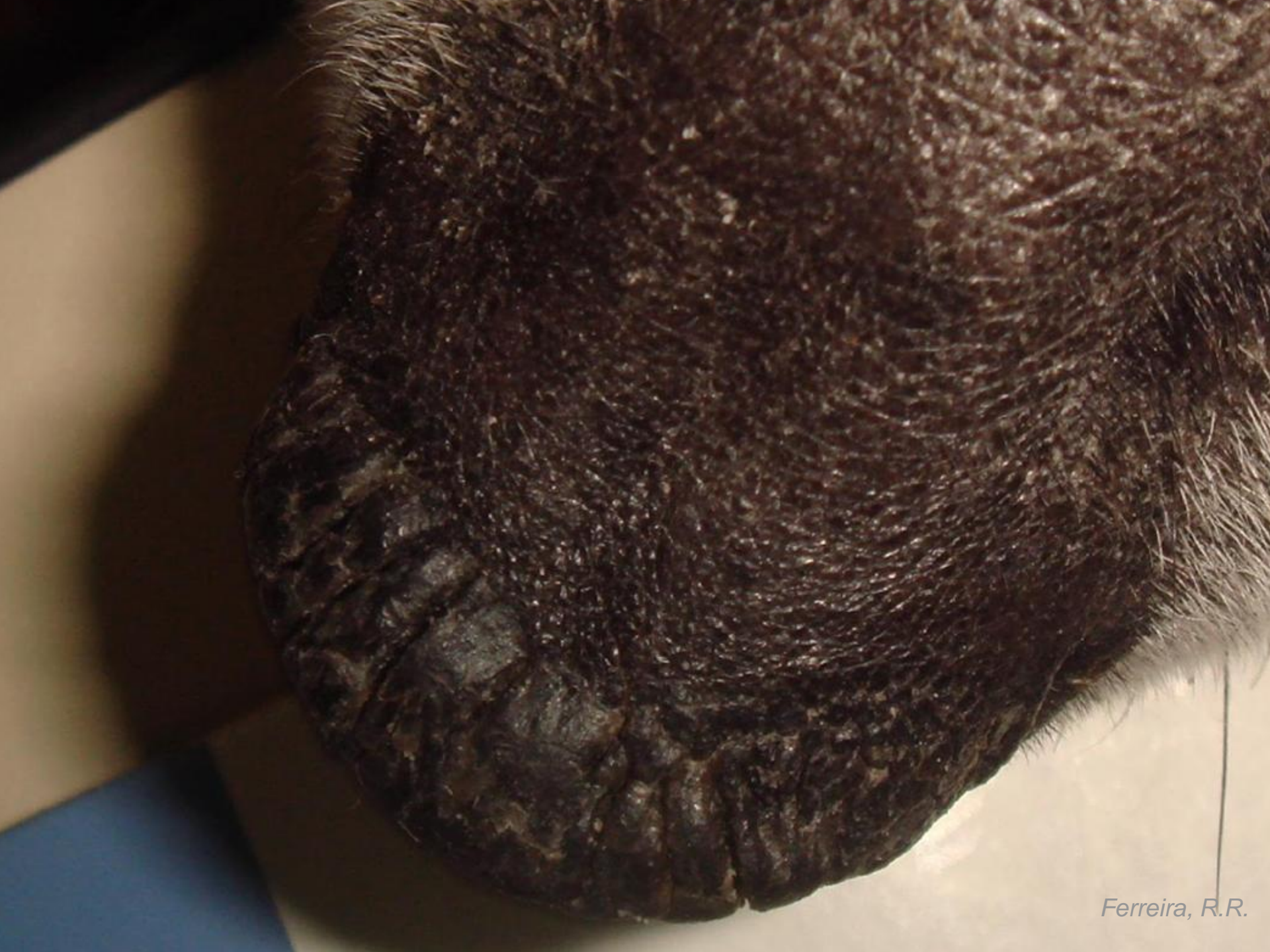Foto: Dr. Mauro Machado



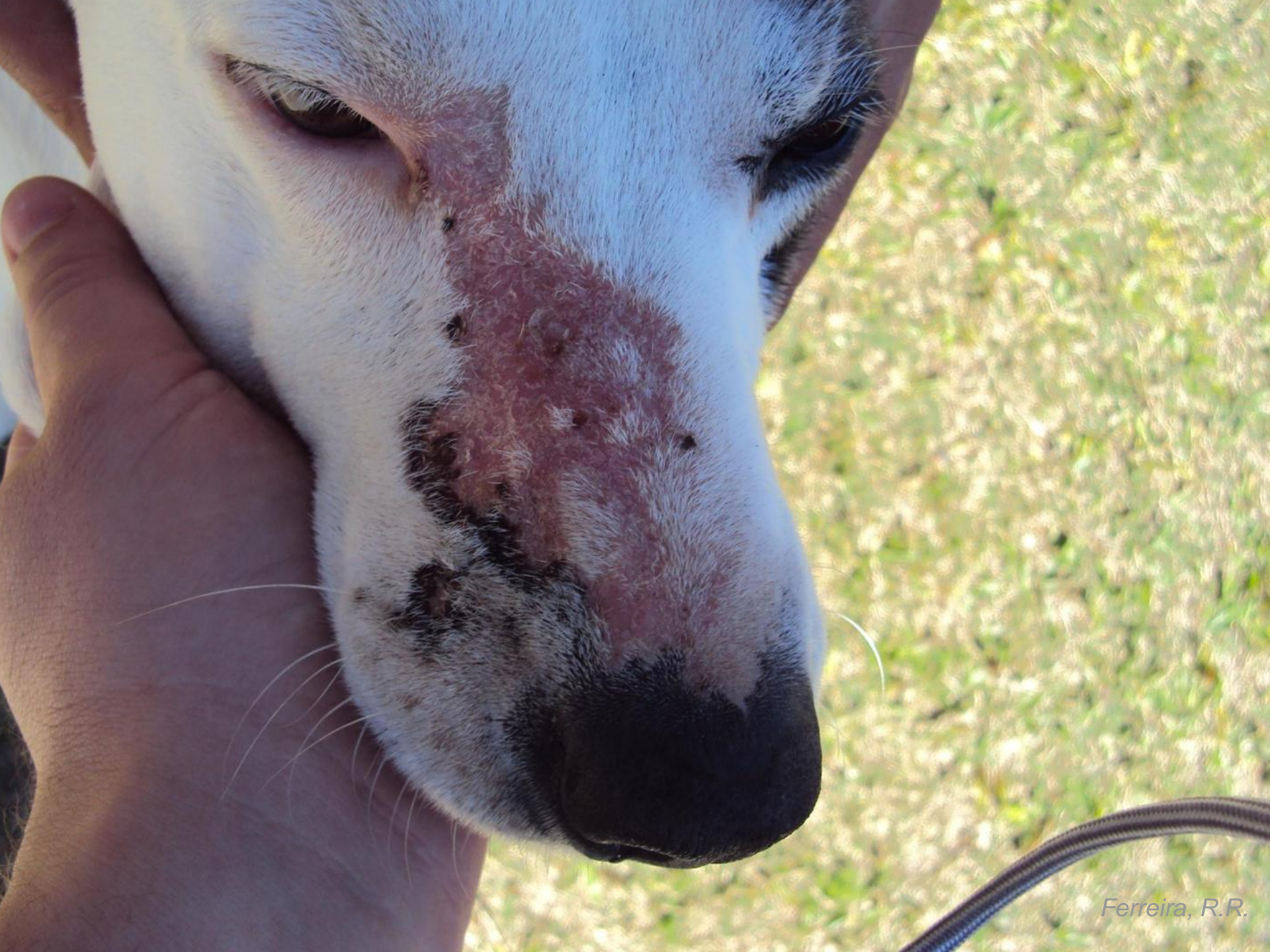DERMATOSES DISQUERATINIZANTES

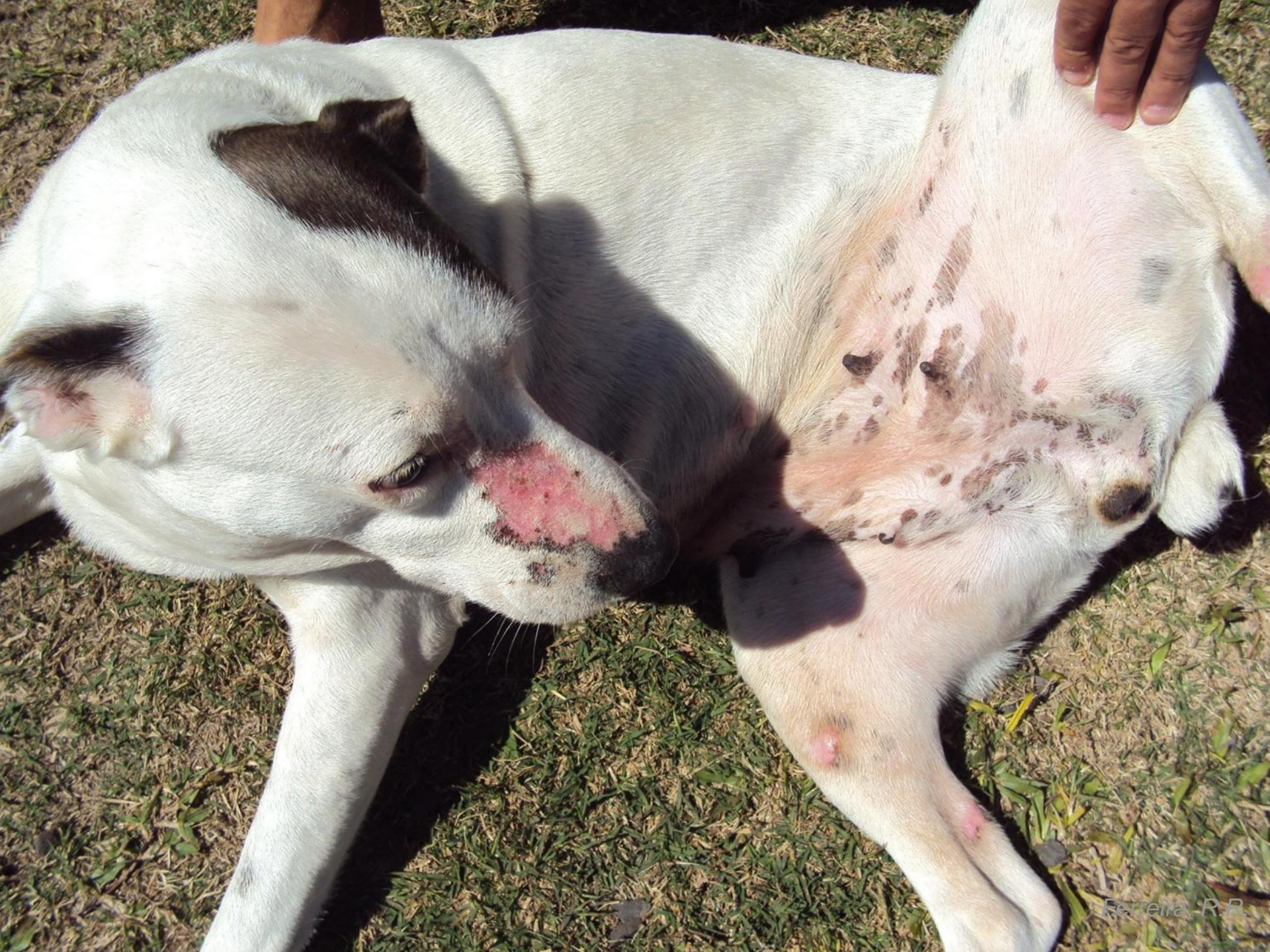


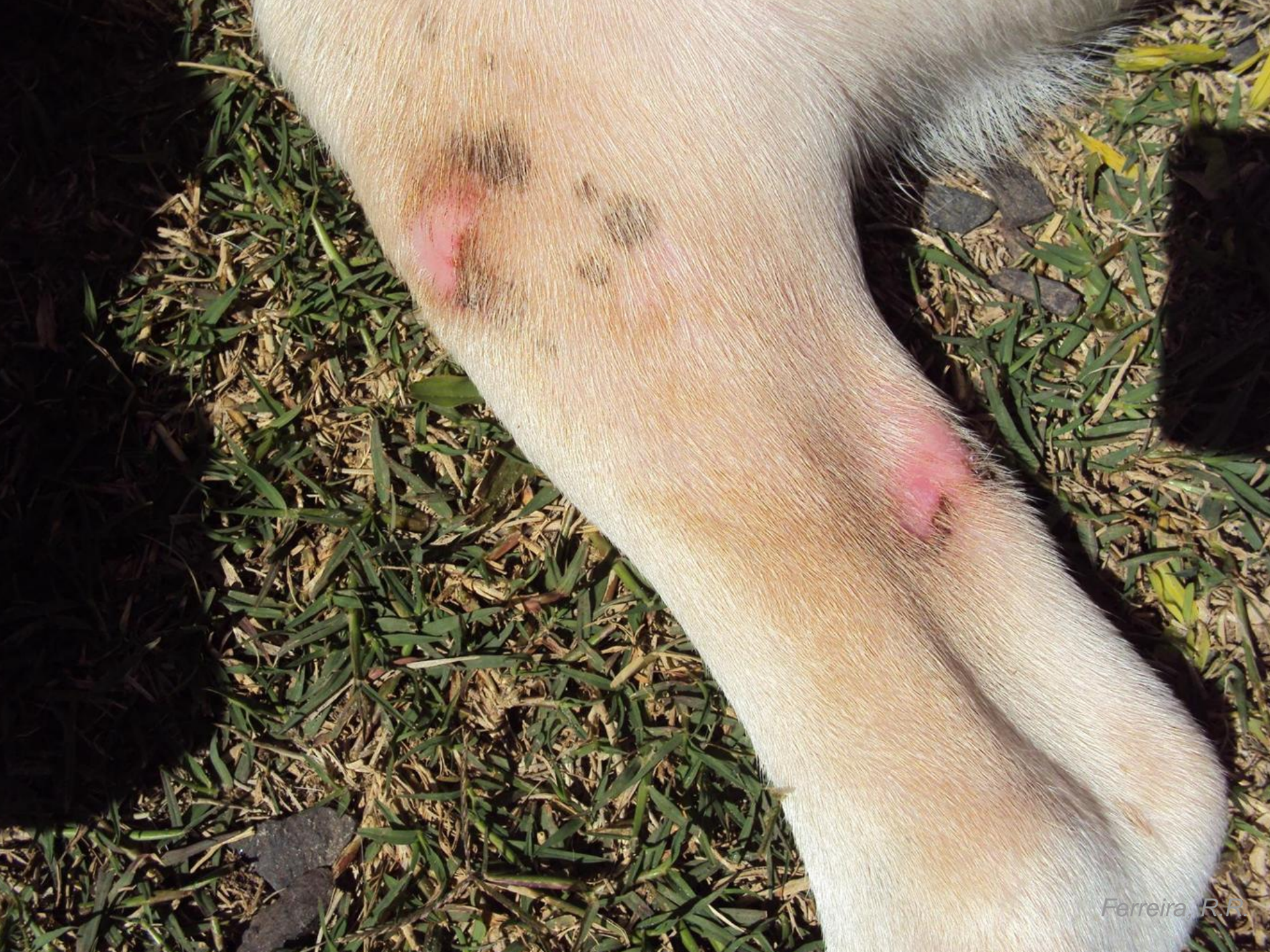
DERMATOSES AMBIENTAIS







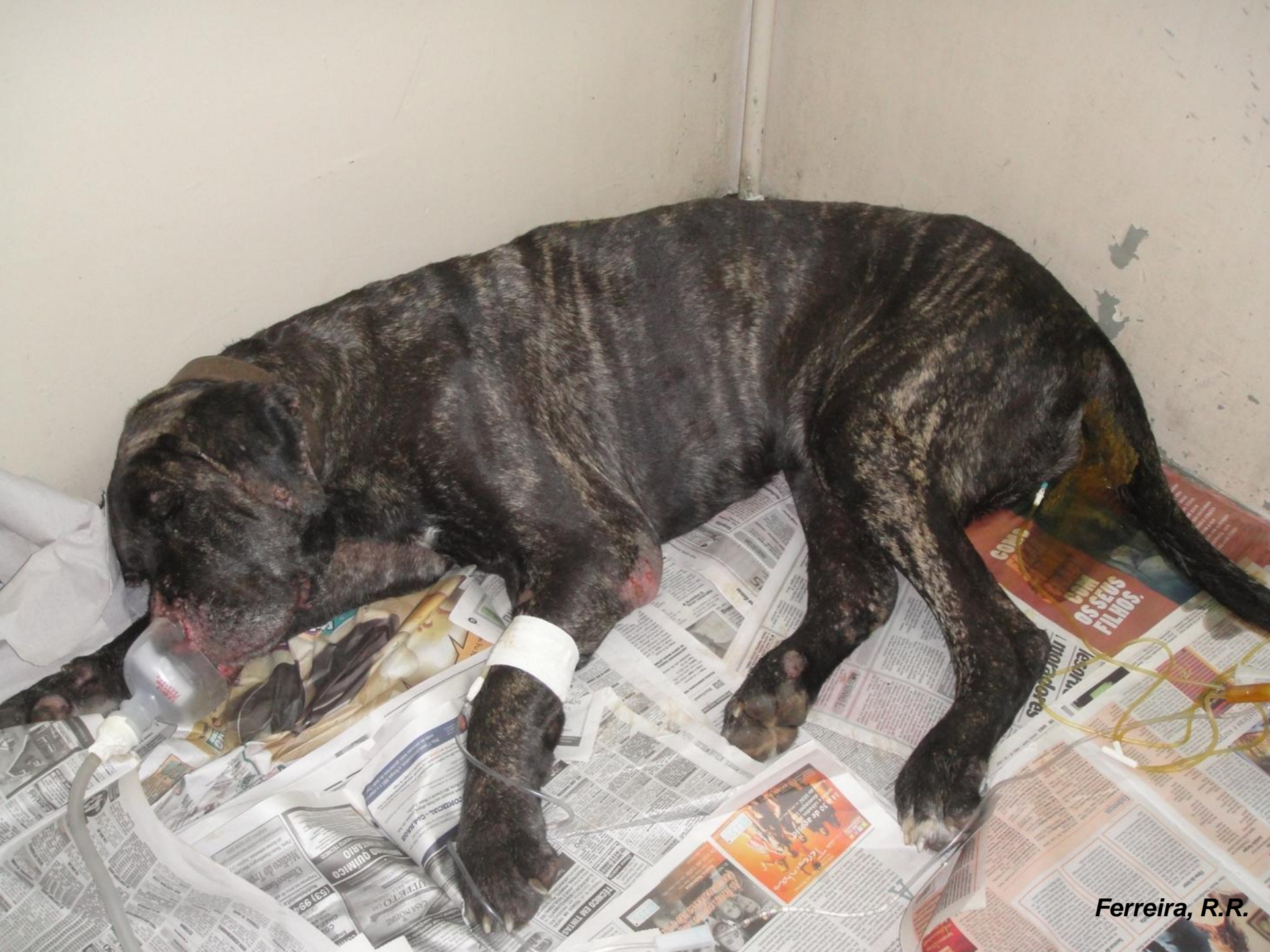



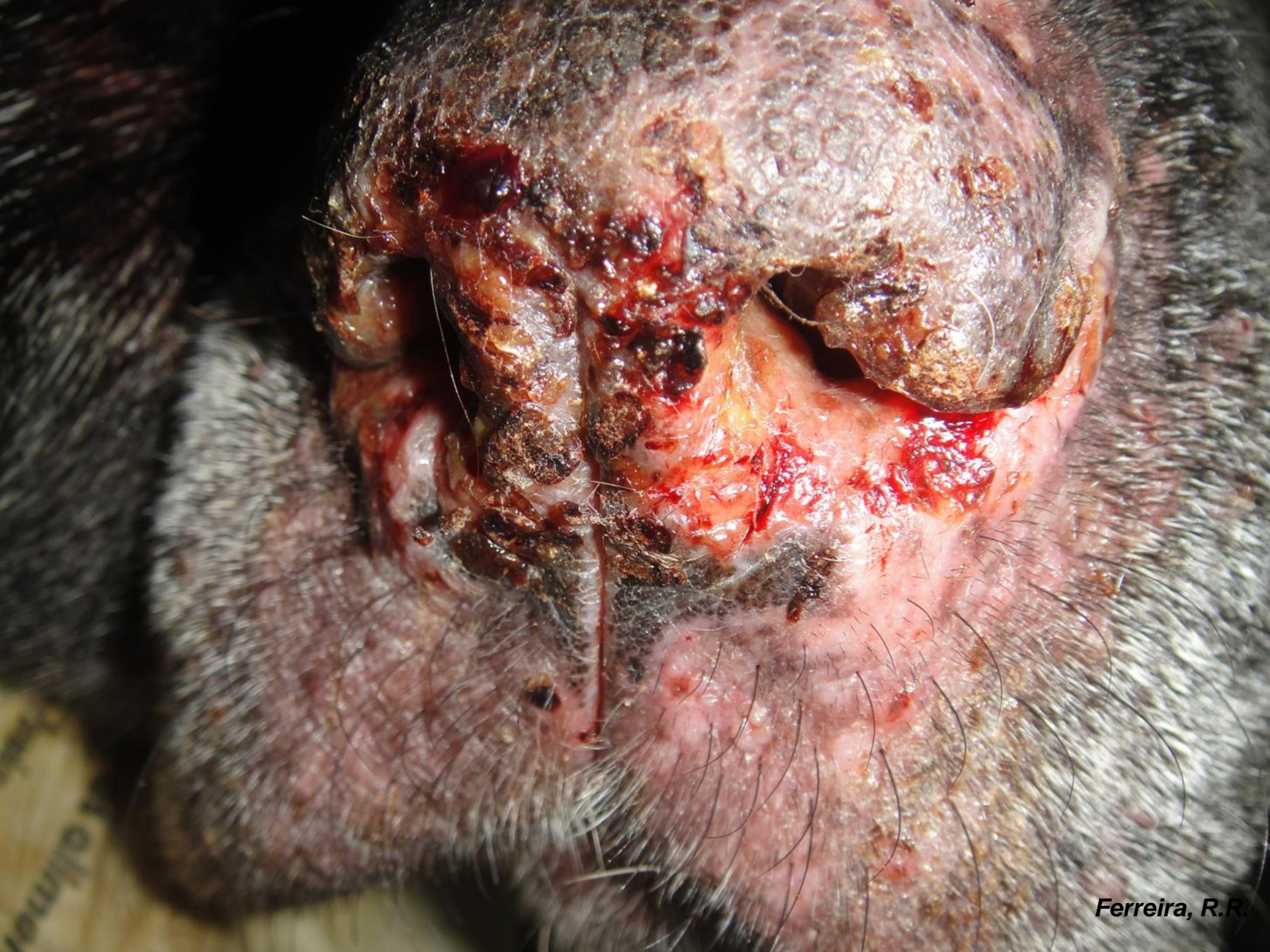DERMATOVET
CURSOS

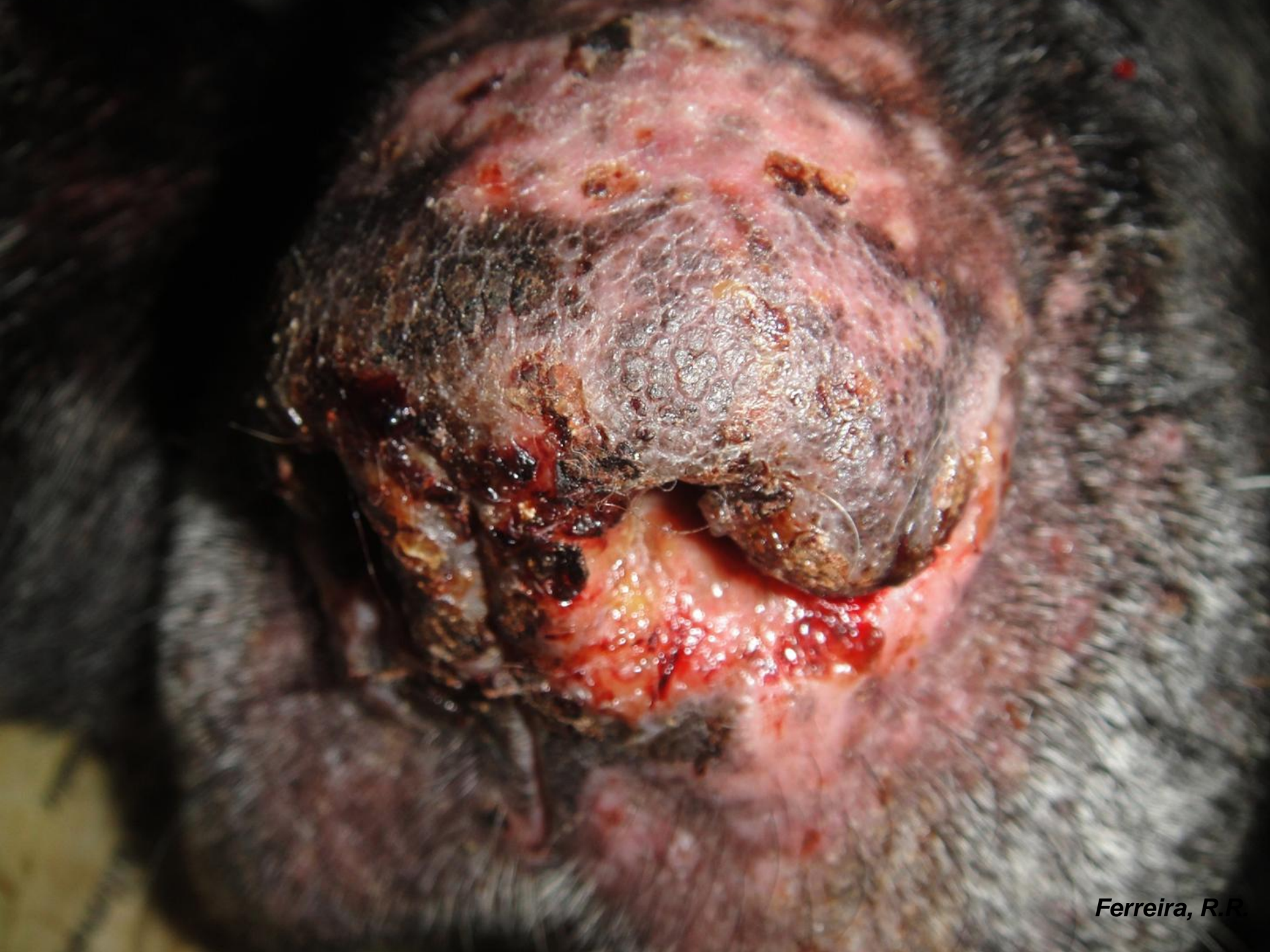CRK202

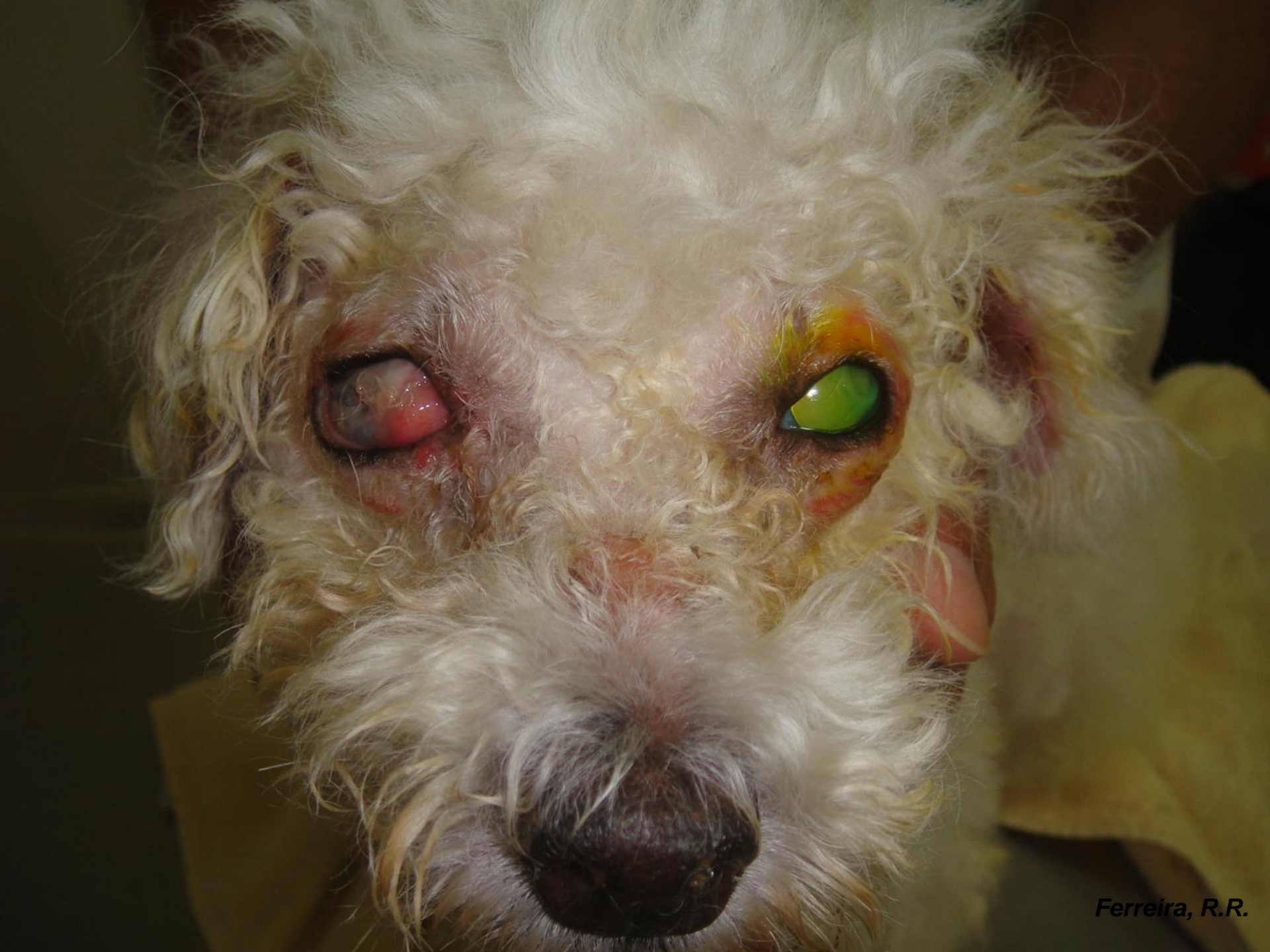DOENÇAS NECRÓTICAS



Ferreira, R.R.

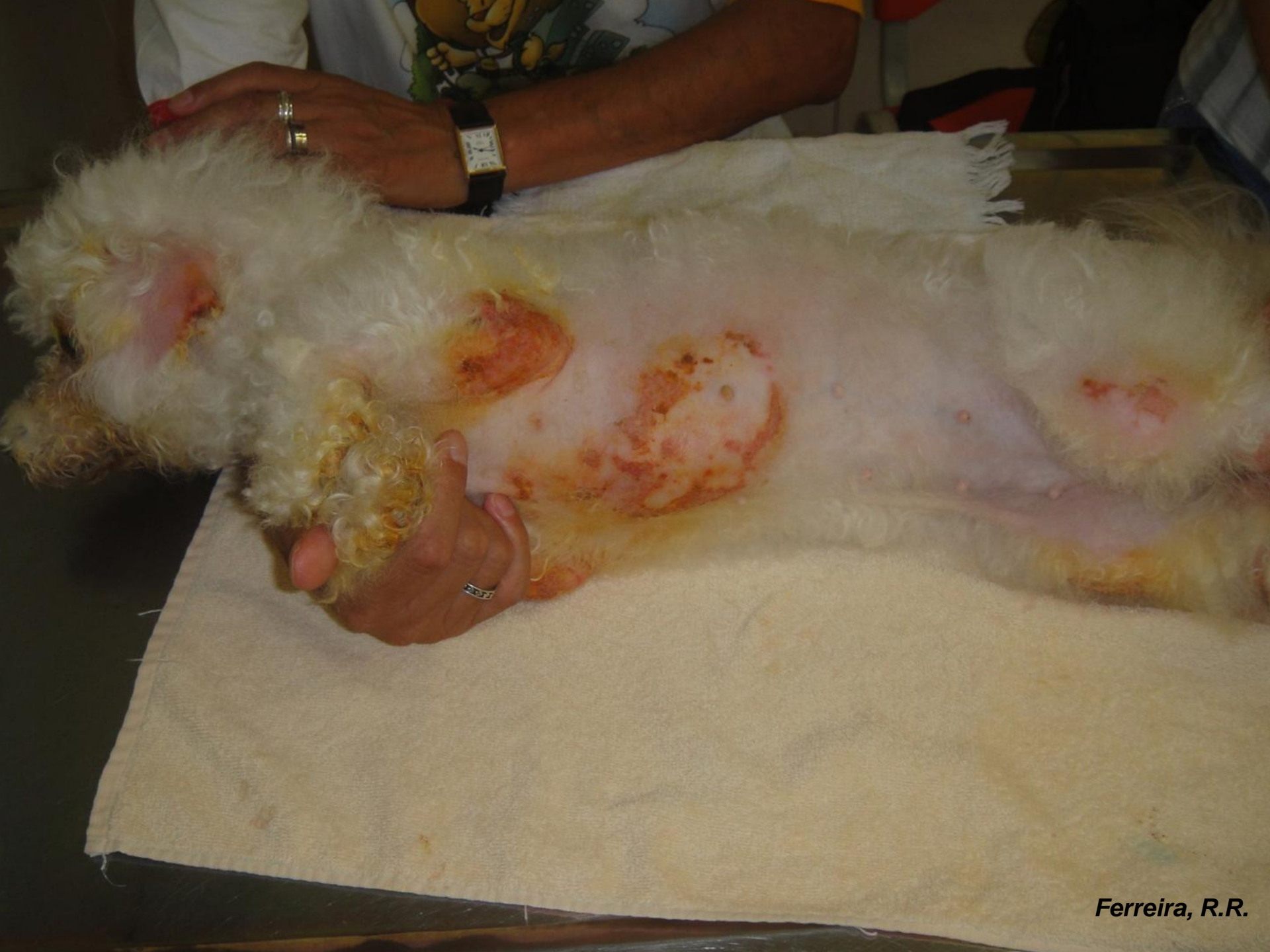


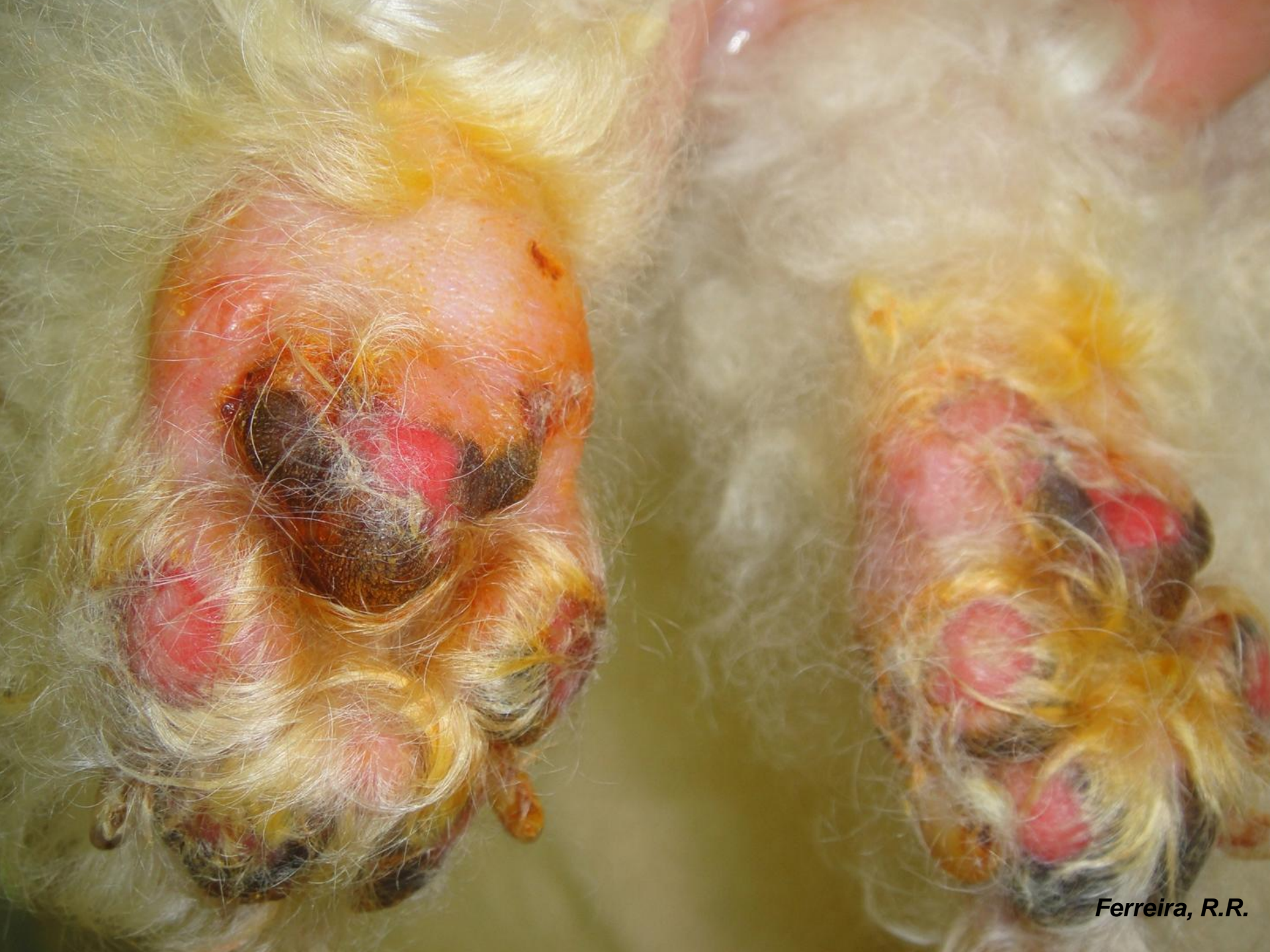


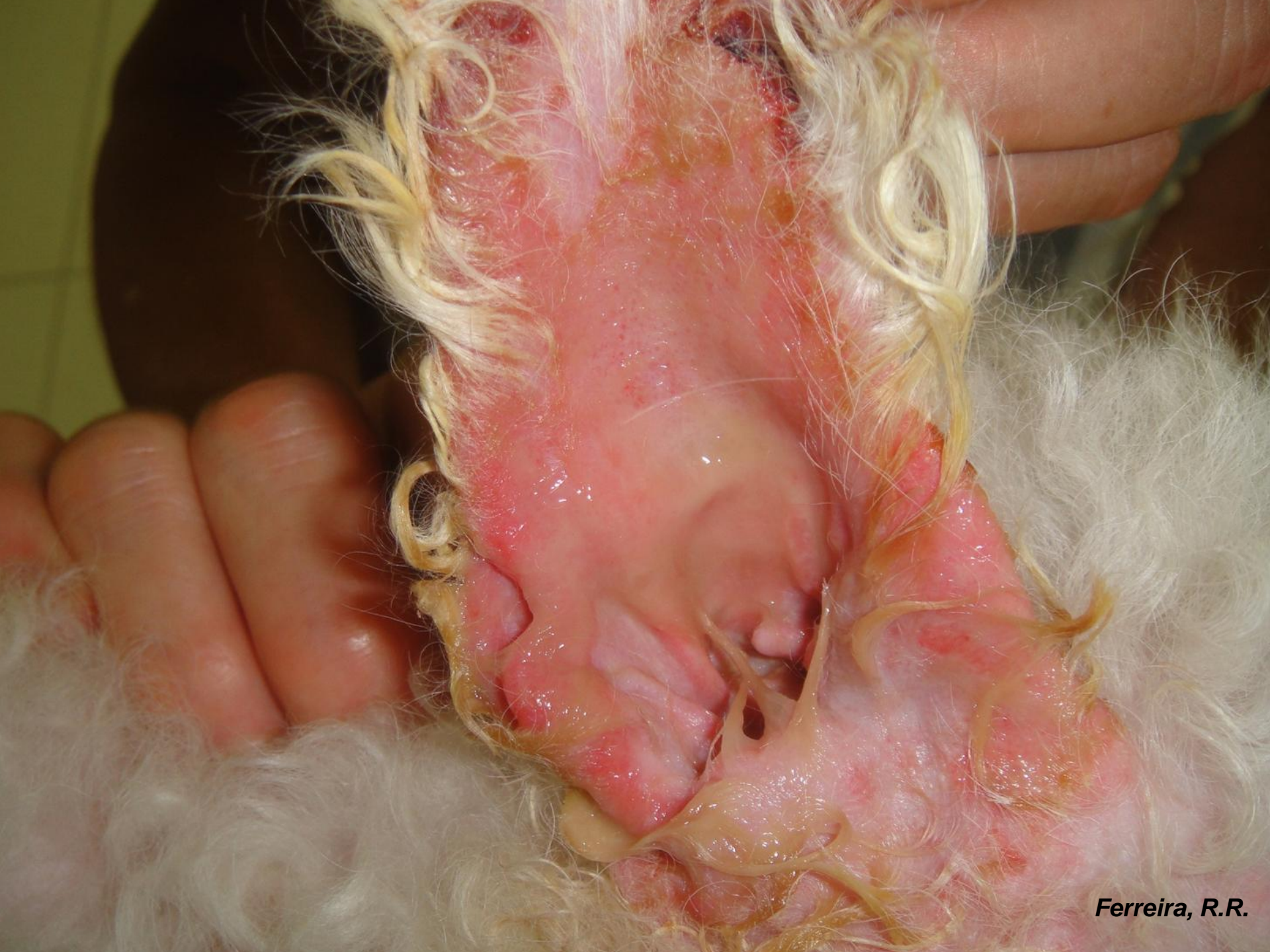

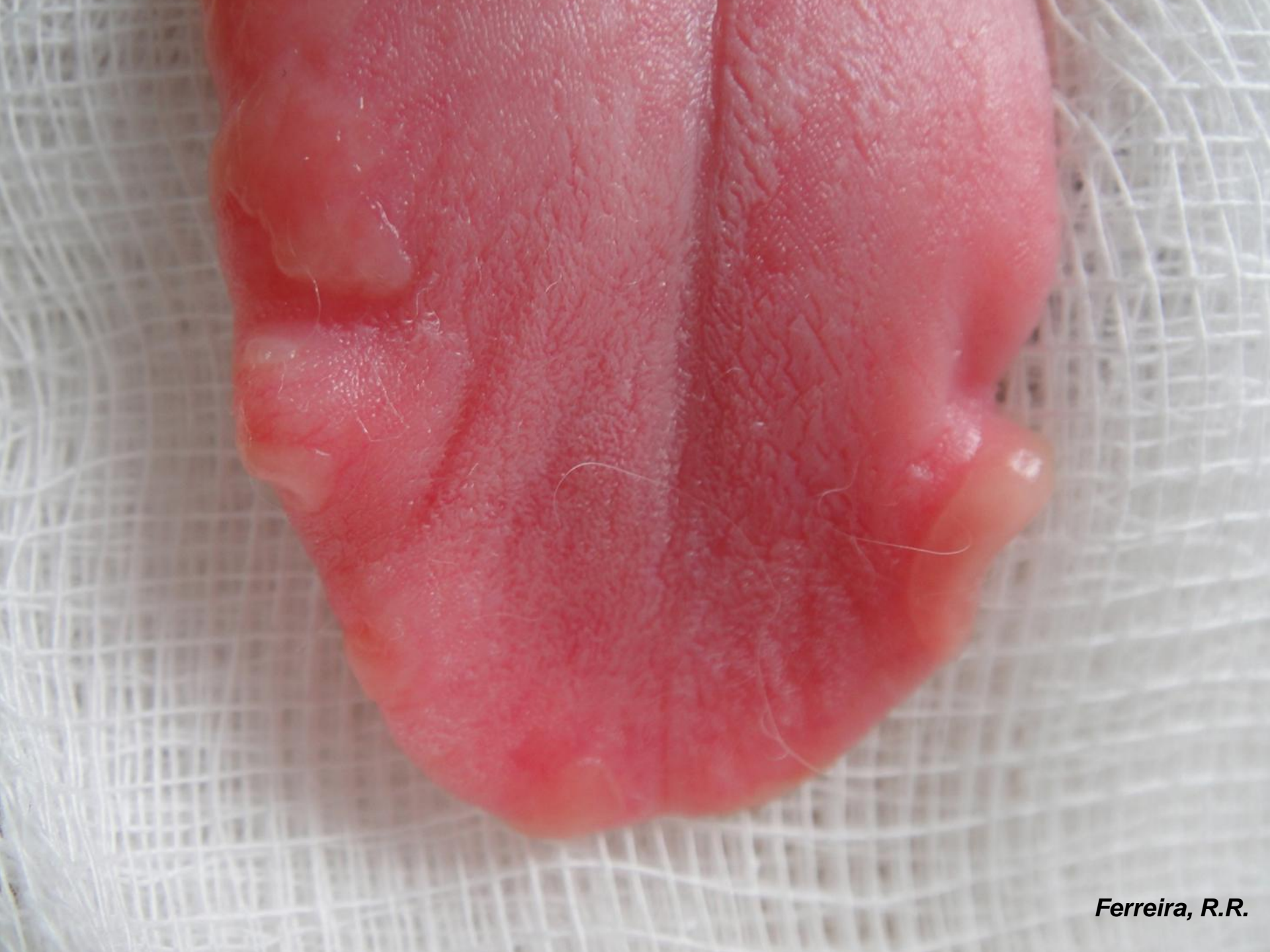Ferreira, R.R.











DERMATOVET
CURSOS

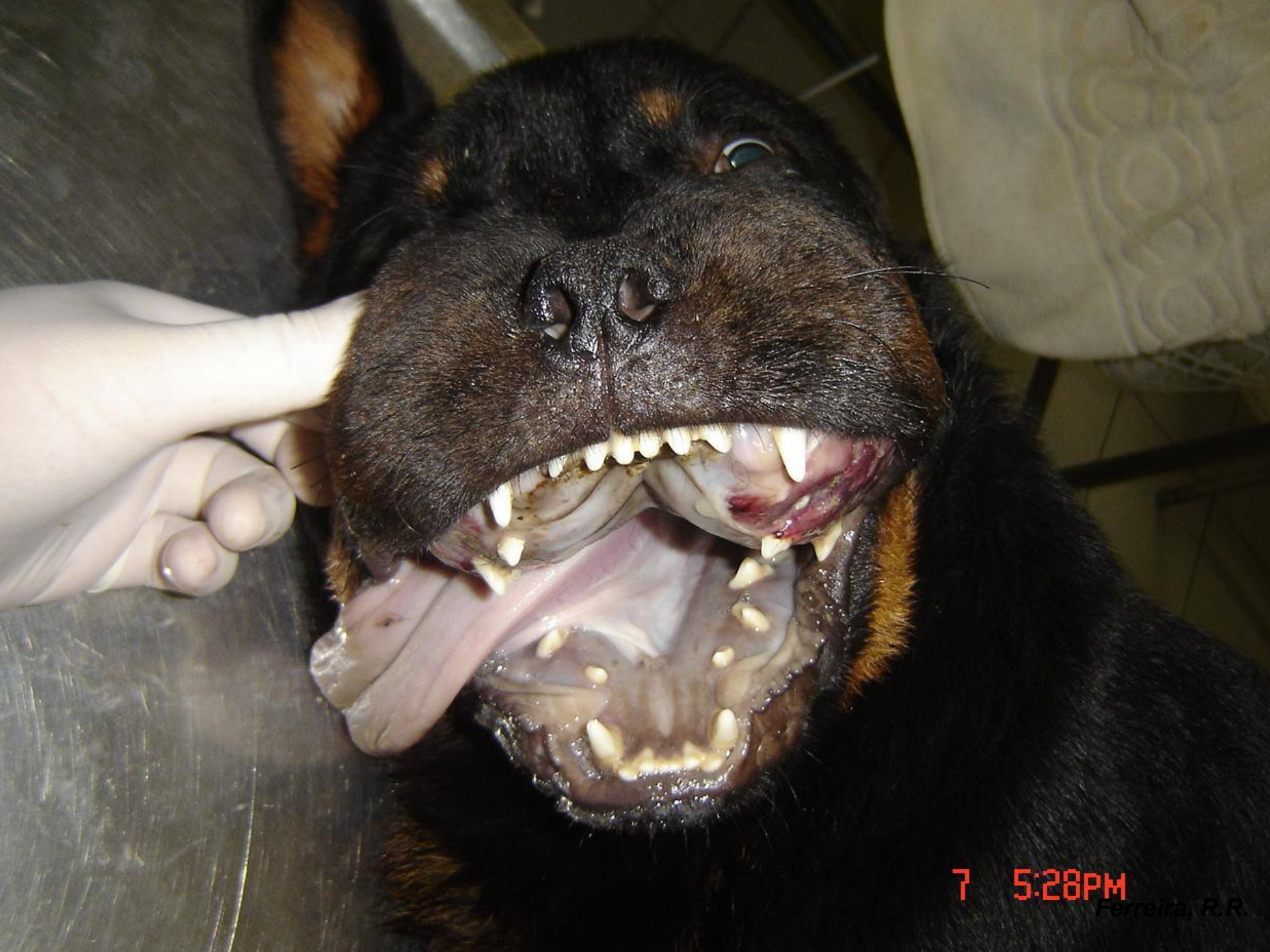CN8202

DOENÇA METABÓLICA



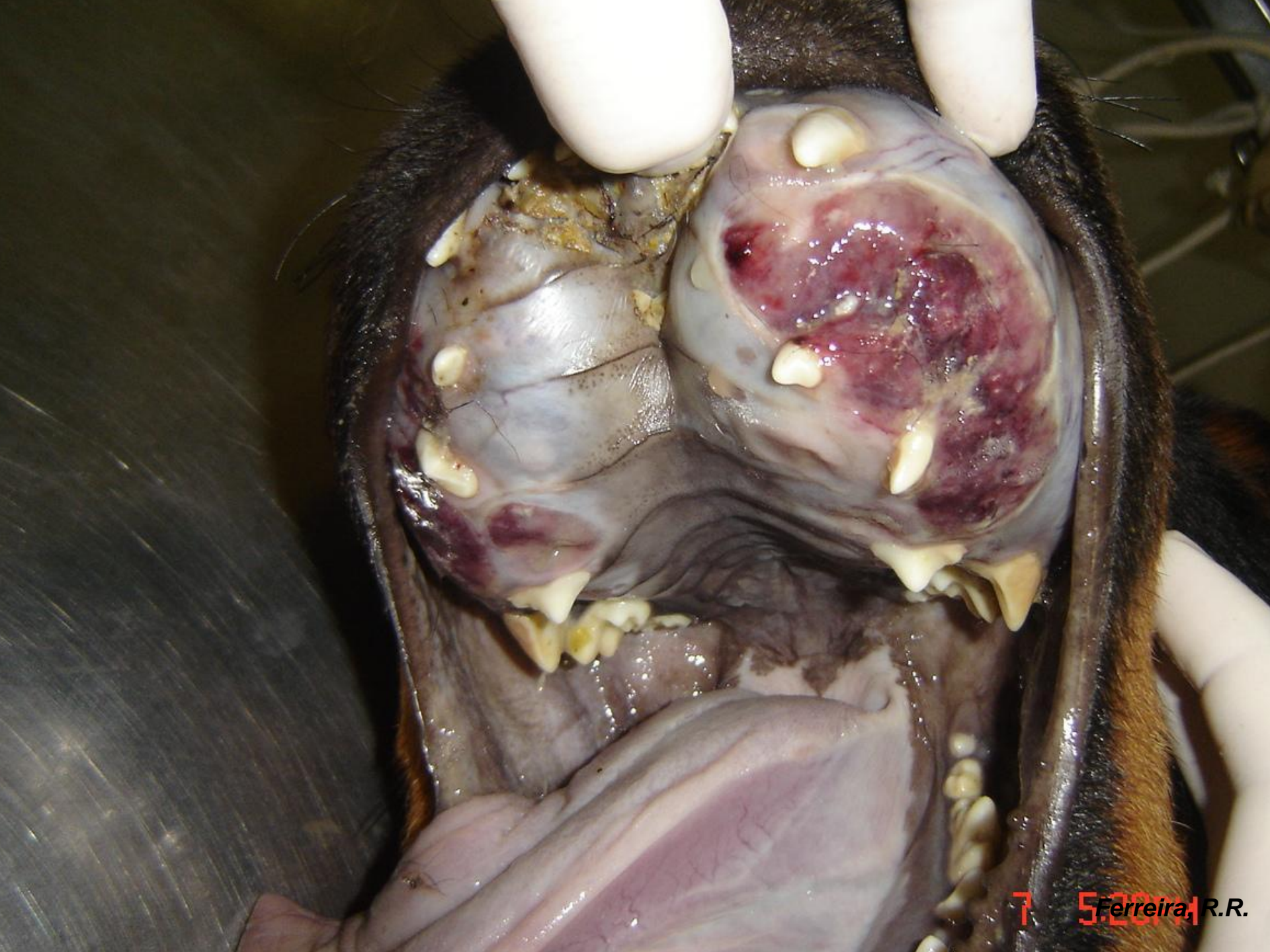5 8:51AM

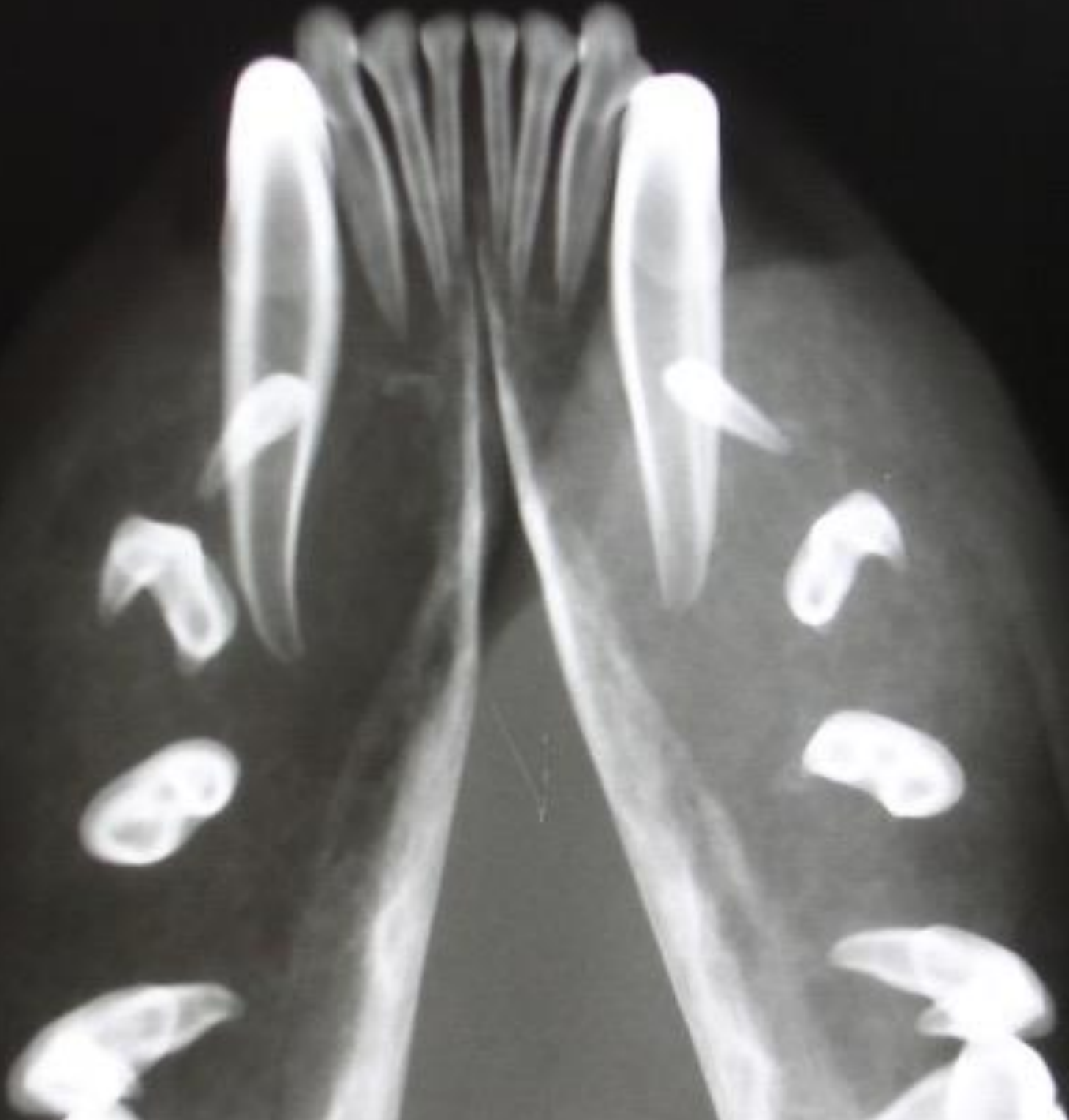
Ferreira, R.R.



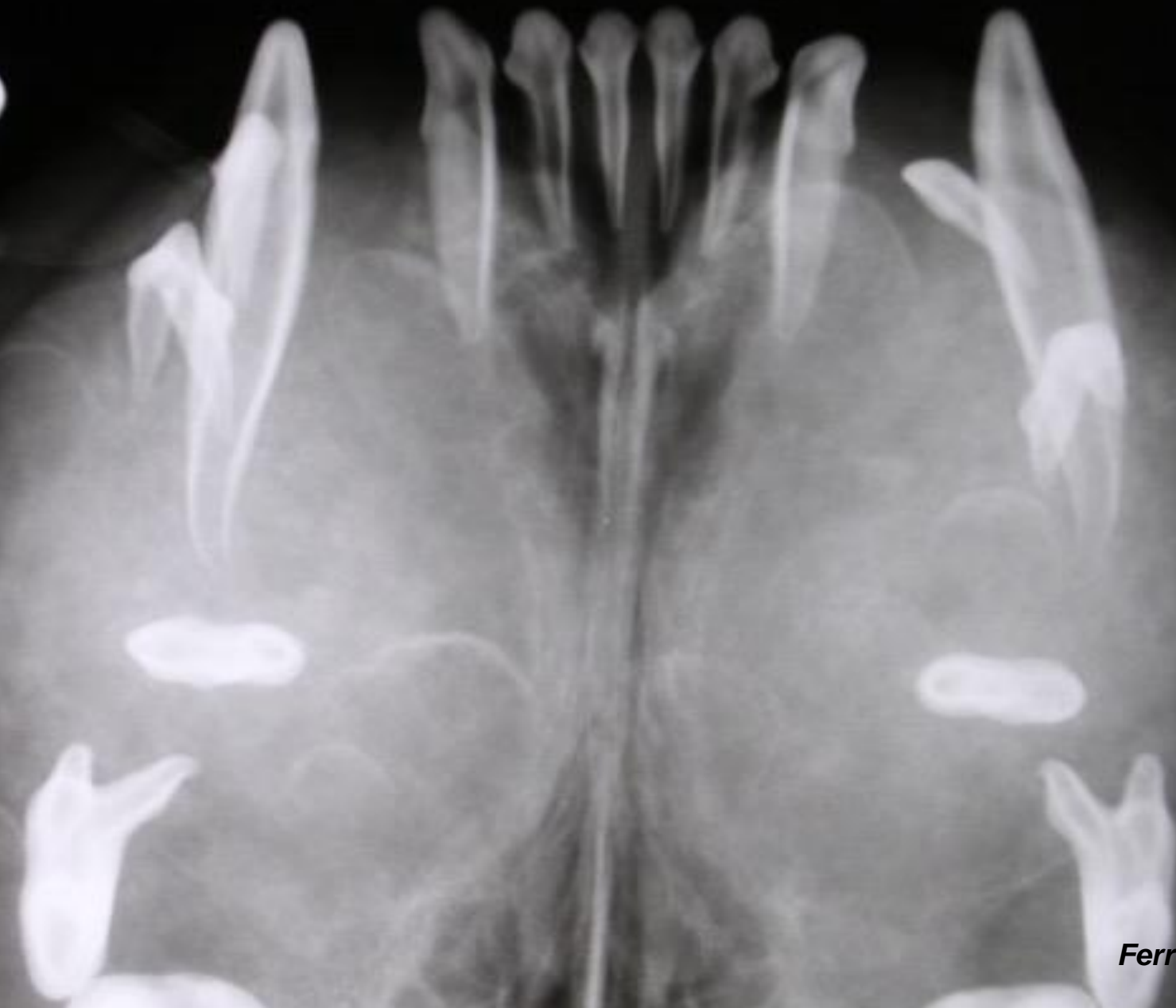
7 5:28PM

Ferreira, R.R.





0e



OBRIGADO!